

A Very Rare Complication of Trans-Radial Cardiac Catheterization: Radial Artery Pseudoaneurysm: Case Report

Trans-Radial Kardiyak Kateterizasyon Sonrası Oldukça Nadir Bir Komplikasyon: Radial Arter Psödoanevrizması

Ertekin Utku ÜNAL,^a
Aytaç ÇALIŞKAN,^a
Başak SORAN TÜRKCAN,^a
Anıl ÖZEN,^a
Sinan Sabit KOCABEYOĞLU,^a
Ahmet SARITAŞ^a

^aClinic of Cardiovascular Surgery,
Türkiye Yüksek İhtisas Training and
Research Hospital,
Ankara

Geliş Tarihi/Received: 09.10.2013
Kabul Tarihi/Accepted: 04.12.2013

*This study was presented as a poster at
Congress of 14th Asian Society for
Vascular Surgery, October 26-29, 2013, İstanbul.*

Yazışma Adresi/Correspondence:
Ertekin Utku ÜNAL
Türkiye Yüksek İhtisas Training and
Research Hospital,
Clinic of Cardiovascular Surgery, Ankara,
TÜRKİYE/TURKEY
utkuunal@gmail.com

ABSTRACT Radial artery pseudoaneurysm is a very rare entity. Iatrogenic pseudoaneurysm after trans-radial cardiac catheterization in a 42-year-old male patient was presented in this paper. Mechanical valve replacement and ascending aorta graft interposition were performed following catheterization. He was on warfarin therapy after surgery. The patient underwent surgical repair of pseudoaneurysm successfully. Although it is a rare complication, great attention and alertness is essential for prevention in patients on anticoagulation therapy.

Key Words: Radial artery; aneurysm, false; heart catheterization; iatrogenic disease

ÖZET Radial arter psödoanevrizması oldukça nadir görülen bir durumdur. Trans-radial kardiyak kateterizasyon sonrası iyatrojenik psödoanevrizma gelişen 42 yaşında erkek hasta sunulmaktadır. Hastaya işlem sonrası mekanik kapak protezi ve asendan aortaya greft interpozisyonu yapıldı ve ardından varfarin tedavisi başlandı. Hastada psödoanevrizma cerrahi olarak başarıyla tedavi edilmiştir. Oldukça nadir olarak görülmesine rağmen, antikoagülasyon uygulanan hastalarda bir hayli dikkat ve ilgili olmak gerekmektedir.

Anahtar Kelimeler: Radial arter; anevrizma, yalancı; kalp kateterizasyonu; iyatrojenik hastalık

Damar Cer Derg 2015;24(1):70-1

Trans-radial approach to cardiac catheterization certainly has advantages in terms of access-site complications.¹ Although very low, complications such as radial artery occlusion, nonocclusive injury, spasm, hand ischemia, nerve damage, bleeding and pseudoaneurysm formation may occur.² In this report, we presented a radial artery pseudoaneurysm in a patient on anticoagulation therapy.

CASE REPORT

A 42-year-old male underwent diagnostic coronary angiography prior to the surgical procedure. Catheterization was performed with the standard heparin regimen (5000 IU IV bolus only once). Hemostatic parameters were normal prior to surgery. Mechanical aortic valve replacement and ascending aorta graft interposition were performed. The patient was on warfarin therapy along with low molecular weight heparin (LMWH) following surgery.

doi: 10.9739/uvcd.2013-37814

Copyright © 2015 by
Ulusal Vasküler Cerrahi Derneği

LMWH therapy was discontinued after 3 days, when effective value of International Normalized Ratio (INR) was achieved (between 2.0 and 3.0). The patient presented with a painless swelling over the site of radial artery access site two months later (Figure 1). Duplex ultrasonography demonstrated a pseudoaneurysm, which failed to close with compression therapy. INR values were between 2.3-3.8 following surgery. On surgical exploration, radial artery pseudoaneurysm with partially thrombosed lumen was exposed, and the pseudoaneurysm was repaired with one stitch of 7/0 polypropylene suture without any complications (Figure 2).

DISCUSSION

The main cause of the pseudoaneurysm is the iatrogenic trauma to the vessel wall as well as some other systemic connective tissue disorders. The most important preventive approach is the adequate compression after the catheterization procedure. Pseudoaneurysms following trans-radial catheterization are extremely rare, with a reported incidence of 0.03% in a very large series.¹ In our case, the main cause of the delayed pseudoaneurysm formation may be the ongoing anticoagulation therapy after mechanical heart valve replacement surgery. Management of a pseudoaneurysm includes compression, thrombin injection and surgical intervention.³ Treatment modalities other than surgery are important and more effective if pseudoaneurysm is diagnosed early. Nevertheless, adequate compression following sheath removal and being alert for the development of a delayed pseudoaneurysm especially in patients on

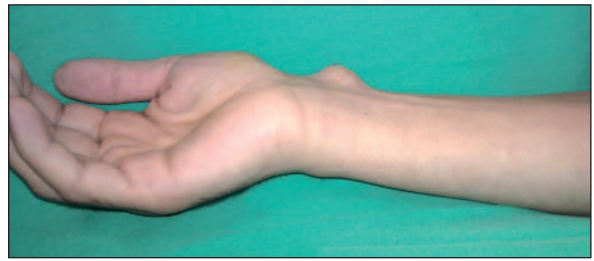


FIGURE 1: Image of right radial pseudoaneurysm. Pseudoaneurysm dimensions were 13.6x8 mm for the patent lumen with partially thrombosed sections on duplex ultrasonography.

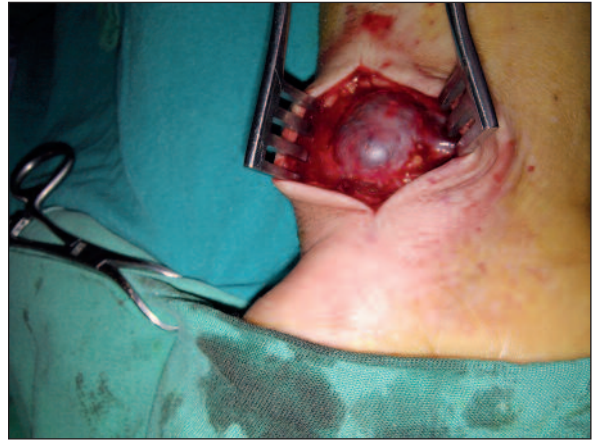

FIGURE 2: Surgical view. The partially thrombosed pseudoaneurysm at the radial artery puncture site was exposed. The pseudoaneurysm's diameter was approximately 1.5 cm. Aneurysmal sac was opened with a compression at the proximal part by forearm tourniquet cuff, and the defect on the radial artery was repaired using a single polypropylene suture.

anticoagulants (especially warfarin) after the procedure are essential for prevention.

Conflict of Interest

Authors declared no conflict of interest or financial support.

REFERENCES

1. Eichhöfer J, Horlick E, Ivanov J, Seidelin PH, Ross JR, Ing D, et al. Decreased complication rates using the transradial compared to the transfemoral approach in percutaneous coronary intervention in the era of routine stenting and glycoprotein platelet IIb/IIIa inhibitor use: a large single-center experience. *Am Heart J* 2008;156(5): 864-70.
2. Kanei Y, Kwan T, Nakra NC, Liou M, Huang Y, Vales LL, et al. Transradial cardiac catheterization: A review of access site complications. *Catheter Cardiovasc Interv* 2011;78(6):840-6.
3. Komorowska-Timek E, Teruya TH, Abou-Zamzam AM Jr, Papa D, Ballard JL. Treatment of radial and ulnar artery pseudoaneurysms using percutaneous thrombin injection. *J Hand Surg Am* 2004;29(5):936-42.