

## How Can a Thrombosed Aortobifemoral Graft be Managed Without Laparotomy?: Surgical Technique

### Tıkalı Aorto-Bifemoral Greft Laparotomi Yapılmadan Nasıl Tedavi Edilir?

Ünal AYDIN,<sup>a</sup>  
Ersin KADİROĞULLARI,<sup>a</sup>  
Onur SEN,<sup>a</sup>  
Salih GÜLER,<sup>a</sup>  
Aydın YILDIRIM<sup>b</sup>

Departments of  
<sup>a</sup>Cardiovascular Surgery,  
<sup>b</sup>Cardiology,  
İstanbul Mehmet Akif Ersoy Thoracic and  
Cardiovascular Surgery Training and  
Research Hospital, İstanbul

Geliş Tarihi/Received: 30.09.2015  
Kabul Tarihi/Accepted: 22.12.2015

Yazışma Adresi/Correspondence:  
Ersin KADİROĞULLARI  
İstanbul Mehmet Akif Ersoy Thoracic and  
Cardiovascular Surgery Training and  
Research Hospital, İstanbul,  
TÜRKİYE/TURKEY  
ersinkadirogullari@gmail.com

Damar Cer Derg 2016;25(2):90-3

doi: 10.9739/uvcd.2015-48124

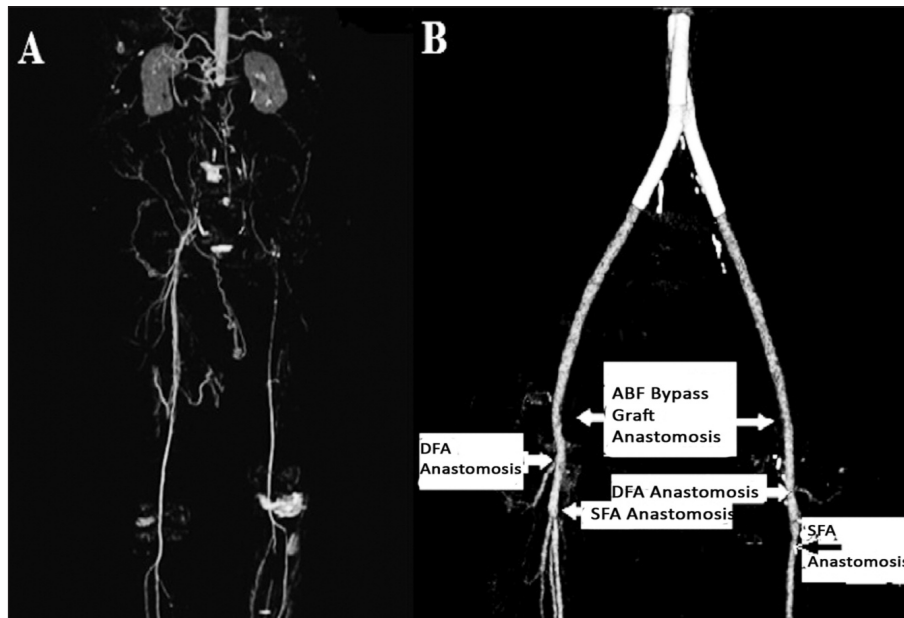
Copyright © 2016 by  
Ulusal Vasküler Cerrahi Derneği

A number of patients admit to vascular surgery department with the symptoms of limb ischemia as a result of thrombosed arterial grafts. Reoperation can be planned to restore blood flow. However reoperation may result in organ trauma, excessive bleeding, and long operation time, which may cause increased surgical mortality and morbidity rates.<sup>1</sup> The combination of endovascular and surgical procedures provides us restoring blood flow without performing a major operation. Endovascular procedures are popular procedures used for treatment of limb ischemia. They were increasingly performed all over the world in the last decade. A hybrid vascular procedure is the combination of endovascular and open surgical techniques.

In this report, we aimed to describe treatment of a symptomatic peripheral arterial disease using a hybrid procedure.

#### CASE REPORT

A 51-year-old man complained of bilateral pedal necrosis and rest pain, and diagnosed with aortobifemoral (ABF) bypass graft thrombosis was evaluated for the treatment with a hybrid procedure. Medical history of the patient revealed ABF bypass operation performed 5 years ago, and crossover femorofemoral bypass operation performed 3 years ago. Those procedures have been resulted with total occlusion of all grafts. Preoperative computerized tomography (CT) scan shows thrombosis of ABF and crossover femorofemoral bypass grafts (Figure 1-A). The risk factors of the patient were hypertension, hyperlipidemia, diabetes mellitus, and chronic obstructive pulmonary disease (COPD). A medical protocol was performed to treat necrosis and rest pain, and control the comorbidities. Subsequently, a hybrid procedure was planned for acquiring limb perfusion. The patients that undergo redo ABF bypass grafting have higher periprocedural complexity due to longer operative time, blood loss, and need for adjunctive procedures. Furthermore, only interventional procedures such as angioplasty or



**FIGURE 1:** A: Preoperative thrombosis of native aorta and ABF bypass graft, computerized tomography; B: Postoperative : Complete reconstruction of iliofemoral arterial flow computerized tomography (ABF: Aortobifemoral, DFA: Deep femoral artery, SFA: Superficial femoral artery).

stenting would not be able to provide adequate limb perfusion. Intimal hyperplasia of native arteries and thrombosis of multiple grafts make the intervention more complex and less successful.

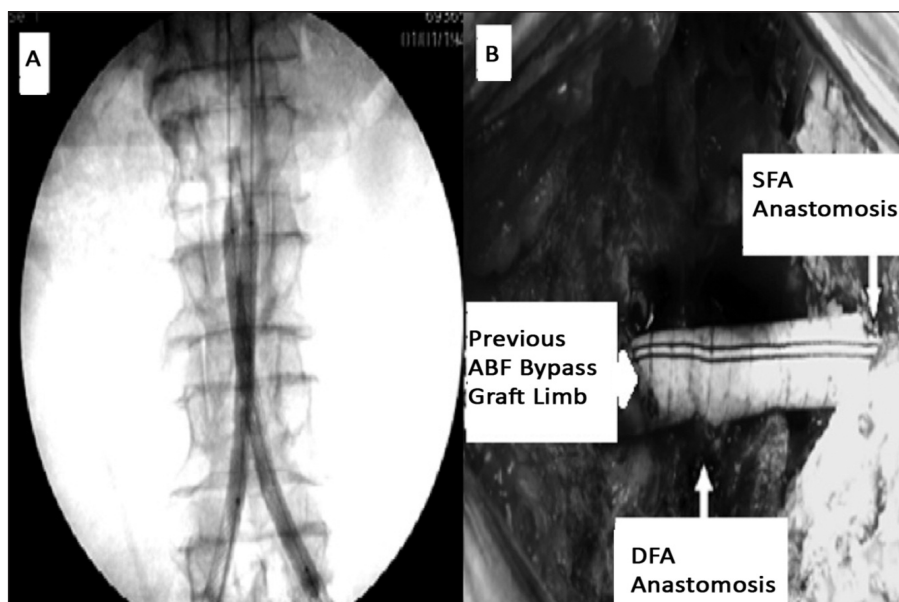
### SURGICAL TECHNIQUE

All procedures were performed in hybrid operating room, using C-arm fluoroscopy system (General Electrics OEC 9900). Our patient underwent a hybrid procedure under general anesthesia. In this case, the hybrid procedure was planned in three stages. The first stage aimed to manage the native femoral arteries, and the graft limbs were anastomosed to femoral arteries. In this way, the native femoral arteries and prosthetic grafts were all exposed, and prosthetic grafts were cut and separated from the anastomosis. Bilateral common femoral arteries (CFA) and left superficial femoral artery (SFA) were occluded, however bilateral deep femoral arteries (DFA) and right SFA were patent. An endarterectomy was performed to left SFA, and retrograde flow was obtained. In this way, bilateral SFA and DFA were prepared for sequential anastomosis. Thrombectomy was performed for occluded graft limbs, however this procedure was unsuccessful, and no arterial flow could be achieved.

After this, 12 F sheathes were inserted into both distal limbs of thrombosed ABF grafts.

Aortobiiliac reconstruction was aimed in the second stage. Hydrophilic guidewires were inserted to cross the both thrombosed graft limbs. As the guidewires were advanced into the aorta, a flush catheter from the right side was placed into the infrarenal segment of the aorta, and an angiogram was obtained. Following the passage of thrombosed graft, two self-expandable stents (10x94 mm Wallstent endoprosthesis, Boston Scientific, Massachusetts, USA) were advanced bilaterally over the guidewire, and placed into the infrarenal aorta at a side-to-side position. After accurate aortic placement, the stents were implanted simultaneously. Predilatation was performed to both stents with balloon dilatation catheters (8.0x8.0 Diamond balloon dilatation catheters, Boston Scientific, Massachusetts, USA). The new arterial lumen was extended with two supplementary stents using the same method (Figure 2-A). Pulsatile blood flow was obtained at the distal limbs of ABF bypass graft subsequent to stent placement.

In the third stage, femoral artery revascularization was planned. At first, inserted sheaths were



**FIGURE 2:** Aortoiliac interventional and surgical reconstructions (ABF: Aortobifemoral, DFA: Deep femoral artery, SFA: Superficial femoral artery).

removed, and the distal segments of grafts were cut to get smooth surfaces. Polytetrafluoroethylene (PTFE) grafts were anastomosed in an end to end fashion to the distal segment of the graft limbs, sequential to DFA, and they were anastomosed end to end to SFA (Figure 2-B). In this way, distal flow was reconstructed, and limb perfusion was obtained (Figure 1-B).

During this procedure, 7500 units of unfractionated heparin was administered intravenously, and activated clotting time (ACT) was measured as 250 seconds.

Pedal ulcers of the patient recovered, and ischemic rest pain disappeared following the hybrid procedure. The patient was administered clopidogrel 75 mg and acetyl salicylic acid (ASA) 81 mg for a minimum of 30 days, followed by lifelong ASA after his discharge from the hospital.

## DISCUSSION

The most important and common complication of ABF bypass surgery is the occlusion of the graft, which threatens the limb viability 80 to 84% in 5 years.<sup>2</sup> In addition, the most common cause of the graft thrombosis is neointimal hyperplasia at the site of anastomosis.<sup>3</sup> Treatment strategy is not clear in those cases, and various techniques have been used

to treat the occlusion. Thrombectomy is the first and the most frequent choice for arterial flow reconstruction in most of the cases. Extra-anatomic bypass and redo anatomic bypass are the following strategies for reconstruction. However thrombectomy was unsuccessful in our case, and no arterial flow could be achieved. Extraanatomic bypass or a redo anatomic bypass procedure would have had high mortality and morbidity rates in this case.

Redo ABF bypass procedure is a complex procedure since exposition of patent abdominal aorta and transfer of graft limbs to femoral artery anastomosis site might result in peritoneal or retroperitoneal organ trauma, extreme bleeding, and long duration of surgery. Occlusion of femoral artery anastomosis due to excessive neointimal hyperplasia made a pure interventional procedure impossible. Therefore, the hybrid procedure became almost obligatory for this case. The surgical team planned the hybrid procedure as femoral artery surgical reconstruction, and aortoiliac endovascular intervention.

Endovascular intervention was considered as the 'kissing stent' technique. The primary concern about kissing stents is the lack of contact between the vessel wall and the opposing stents, which may

prevent endothelialization and cause thrombosis, hemolysis or induce intimal hyperplasia because of high shear stress.<sup>4</sup> Primary patency rates were reported between 76% and 63% in 1-5 years, and they seem lower than those reported for surgery.<sup>5</sup> Greiner et al. reported that kissing stent technique for treatment of complex iliac occlusive disease should be limited to patients with poor prognosis due to serious comorbidities, and to those who are at high risk for surgery.<sup>6</sup> This case also had a high surgical mortality risk, however the patency rates were expected higher compared to the routine cases. Since the distal arterial outflow tract was sur-

gically reconstructed, and a good flow pattern was achieved. The surgical risks were minimized.

## CONCLUSION

The hybrid technique, combination of intervention and surgery, may be an effective, less invasive and safe treatment method in our case, who had late graft occlusion and a high risk for surgical reconstruction.

## Conflict of Interest

*Authors declared no conflict of interest or financial support.*

## REFERENCES

1. Desgranges P, Cron J, Allaire E, Becquemin JP, Mellièrè D. Late reoperations after surgical and endovascular lower limb revascularisation. *Eur J Vasc Endovasc Surg* 2002;23(1): 44-8.
2. De Vries S, Hunick M. Results of aortic bifurcation grafts for aortoiliac occlusive disease: a meta-analysis. *J Vasc Surg* 1997;26(4):558-69.
3. Imparato AM, Bracco A, Kim GE, Zeff R. Intimal and neointimal fibrous proliferation causing failure of arterial reconstructions. *Surgery*. 1972;72(6):1007-17.
4. Brewster DC, Meier GH 3rd, Darling RC, Moncure AC, LaMuraglia GM, Abbott WA. Reoperation for aortofemoral graft limb occlusion: Optimal methods and long-term results. *J Vasc Surg* 1987;5(2):363-74.
5. Frisch N, Bour P, Berg P, Fiévé G, Frisch R. Long-term results of thrombectomy for late occlusions of aortofemoral bypass. *Ann Vasc Surg* 1991;5(1):16-20.
6. Greiner A, Dessl A, Klein-Weigel P, Neuhauser B, Perkmann R, Waldenberger P, et al. Kissing stents for treatment of complex aortoiliac disease. *Eur J Vasc Endovasc Surg* 2003; 26(2):161-5.