

Renal allograft dysfunction due to iliac artery occlusion: Cross-over femoro-femoral bypass saves the day

İliyak arter tıkanıklığına bağlı renal allogreft disfonksiyonu: Cross-over femoro-femoral baypas günü kurtarır

Tolga Demir¹, Mehmet Ümit Ergenoğlu², Nursen Tanrikulu³, Abdurrahman Ekinci², Ergun Demirsoy²

¹Department of Cardiovascular Surgery, Beylikdüzü Kolan Hospital, İstanbul, Turkey

²Department of Cardiovascular Surgery, Kolan International Hospital, İstanbul, Turkey

³Department of Anesthesiology and Reanimation, Kolan International Hospital, İstanbul, Turkey

ABSTRACT

Isolated iliac artery stenosis or occlusion is a rare complication after renal transplantation. There are two treatment methods for suprarenal arterial stenosis, including percutaneous angioplasty with or without stents and surgical revascularization. Herein, we present a case of proximal common iliac artery stenosis with a patent renal artery who presented with hypertension and allograft dysfunction following transplantation and underwent cross-over femoro-femoral bypass. This case demonstrates that cross-over femoro-femoral bypass provides sufficient retrograde flow to perfuse renal allograft.

Keywords: Femoral artery; kidney transplantation; vascular surgery.

ÖZ

Böbrek nakli sonrasında görülen iliyak arter darlığı veya tıkanıklığı nadir bir komplikasyondur. Stent kullanılan veya kullanılmayan perkütan anjiyoplasti ve cerrahi revaskülarizasyon olmak üzere suprarenal arter darlığının tedavisinde kullanılan iki yöntem vardır. Bu yazıda, renal arteri açık olan bir hastada nakil sonrasında hipertansiyon ve allogreft disfonksiyonu ile ortaya çıkan ve proksimal ana iliyak arter darlığının cross-over femoro-femoral baypas ile tedavi edildiği bir olgu sunuldu. Bu olgu, cross-over femoro-femoral baypasın renal allograftın perfüzyonu için yeterli retrograd akım sağladığını göstermektedir.

Anahtar sözcükler: Femoral arter; böbrek nakli; damar cerrahisi.

Complications of atherosclerosis following renal transplantation are several times greater than that in the normal population. However, aorto-iliac occlusive disease following renal transplantation is a rare complication with an incidence of 0.37 to 1.5.^[1,2] There are several alternatives to treat this unfortunate condition, such as percutaneous procedures with or without balloon dilatation, and endovascular stent graft placement.^[3] However, surgical revascularization using aorto-iliac bypass or endarterectomy is the mainstay of the treatment. Herein, we present a case of proximal common iliac artery stenosis with a patent

renal artery who presented with hypertension and allograft dysfunction following transplantation and treated with cross-over femoro-femoral bypass.

CASE REPORT

A 43-year-old white male patient with end-stage renal disease received his first living-related renal transplant in 1998. An allograft kidney was implanted into the right iliac fossa with the construction between the donor renal artery and recipient right external iliac artery. His clinical course after the first renal

Received: September 26, 2014 *Accepted:* December 01, 2014

Correspondence: Tolga Demir, MD. Beylikdüzü Kolan Hospital Kalp ve Damar Cerrahisi Bölümü, 34528 Beylikdüzü, İstanbul, Turkey.
e-mail: dr.tolgademir@gmail.com

Citation:

Demir T, Ergenoğlu MÜ, Tanrikulu N, Ekinci A, Demirsoy E. Renal allograft dysfunction due to iliac artery occlusion: Cross-over femoro-femoral bypass saves the day. Damar Cer Derg 2017;26(2):62-65.

transplantation was stable until 2010. Due to chronic allograft nephropathy and worsening of kidney function requiring three sessions of hemodialysis per week, the patient received a second living-related renal transplant in 2011. The second allograft kidney was implanted in the left iliac fossa with the same technique, as explained above (the construction between the donor renal artery and the recipient left external iliac artery). No sign of atherosclerotic changes were observed during surgery. However, 16 months later from the second transplant surgery, serum creatinine level progressively increased to 1.8 mg/dL. A percutaneous renal allograft biopsy was carried out under ultrasonography guidance, and showed no signs of rejection. Physical examination revealed a diminished left femoral pulse, compared to the right femoral pulse. The blood pressure was also moderately increased (170/90 mmHg). Due to the presence of allograft renal function deterioration and diminished left side femoral artery pulse, left iliac artery stenosis was suspected. The patient underwent color Doppler ultrasonography examination which revealed a normal allograft size and echogenicity of the renal parenchyma. The flow velocity in the allograft renal artery and left external iliac artery were measured as 16.2 cm/s and 33.4 cm/s, respectively with changes of the flow patterns to monophasic in both arteries. The mean renal arterial resistive indexes from three different poles were measured as 0.4 to 0.5. After interpreting the data, the patient was scheduled for conventional aorto-femoro-popliteal angiography for further and detailed evaluation of pathology,

which revealed total occlusion of the left common iliac artery proximal to the anastomosis (Figure 1a). The right common iliac artery was patent.

Due to type and location of the occlusion, initially decision was made to treat patient with percutaneous endovascular stent implantation. The left trans-femoral approach was performed using the percutaneous Seldinger technique. However, after several attempts, guidewires were unable to be advanced into the proximal part of the left common iliac artery.

Due to the high risk of surgery in abdominal reoperation and difficulty of performing renal allograft translocation due to previous renal transplantation, alternative revascularization options were discussed with the transplantation team. Since the renal allograft artery was widely open with no flow pattern abnormalities and significant total occlusion of the left common iliac artery, the decision was made for extra-anatomic bypass with the insertion of a synthetic tube graft between the right and left femoral arteries (cross-femoral). A written informed consent was obtained from the patient.

A 8 mm Gore-Tex polytetrafluoroethylene synthetic tube graft with rings around was inserted extra-anatomically between the right and left femoral arteries (Figure 1b). Postoperative period was uneventful. Both pedal pulses were present. Serum creatinine levels were 1.4 mg/dL and 1.3 mg/dL on the postoperative first and third days, respectively. Color Doppler ultrasonography showed normal flow velocity and patterns in the left femoral and distal arteries during

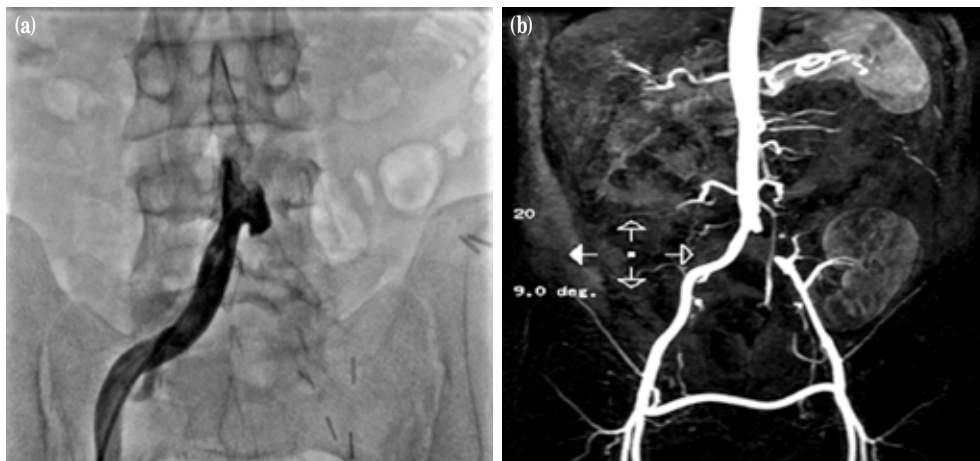


Figure 1. (a) Conventional angiography showing total occlusion of the left common iliac artery proximal to the anastomosis. (b) Magnetic resonance imaging angiography showing cross-over femoro-femoral bypass graft, and retrograde perfusion of renal allograft.

follow-up. The flow velocity increased in both renal allograft artery (37.4 cm/s) and left external iliac artery (92.2 cm/s), compared to the preoperative values. The mean renal arterial resistive index from three different poles was measured as 0.7. One month after the operation, the laboratory values of blood urea nitrogen and serum creatinine levels were normalized with the values of 30 mg/dL and 1.1 mg/dL, respectively. The distal pulses of both lower extremities were also normal on physical examination. The patient's recovery was uneventful and he was discharged from the hospital on the fifth postoperative day. His postoperative course was symptom-free and uneventful during the 12 months of follow-up.

DISCUSSION

Renal transplantation is the preferred treatment for most patients with end-stage renal disease. Atherosclerotic complications are more common in renal transplant recipients with the incidence of 3 to 4%, compared to normal population.^[4] Associated risk factors include hypertension, abnormal lipid and lipoprotein profiles, and increased serum homocysteine levels.^[5] The most common type of vascular problem is the stenosis of the renal allograft artery at the site of anastomosis with the recipient iliac artery, mostly due to improper surgical technique. However, isolated iliac artery stenosis or occlusion is a rare complication after renal transplantation with an incidence between 0.37 and 1.5%.^[2] There are no specific findings for the renal allograft or iliac artery stenosis. Most of these patients present with elevated serum creatinine levels, bruits, lower extremity claudication, and renal allograft-mediated hypertension secondary to stenosis of the iliac artery, proximal to the site of graft anastomosis.^[6]

The management of these patients are challenging due to high-risk of their profile. However, there are two methods for the treatment of suprarenal arterial stenosis including percutaneous angioplasty with or without stents, and surgical revascularization. Percutaneous angioplasty which is a well-established first-line treatment with less morbidity for atherosclerotic lesions can be used for both renal allograft and native iliac artery stenosis. It has 90 to 95% initial patency rates which decreases to 75 to 90% in three to five years of follow-up.^[7] However, this method includes several drawbacks, such as stent migration, occlusion

of side branches, late thrombosis, and embolization.^[7] Renal allograft dysfunction due to a contrast agent is another concern in this patient population undergoing percutaneous angioplasty.

Furthermore, aorto-iliac surgery in renal transplant recipients carries the risk of inducing a prolonged period of ischemia which can affect transplanted kidney survival and high risk of morbidities. Since Freeman and Leeds first described the femoral to femoral cross-over graft in 1952, extra-anatomical bypass procedures have been a recognized method of lower limb revascularization in high-risk patients who cannot tolerate aortic cross-clamping, or in those with a hostile abdomen or where angioplasty fails.^[8-10] There are few reports using cross-over femoro-femoral bypass in renal transplant patients for rescuing the allograft.^[11,12] Cross-femoral bypass provides sufficient retrograde flow to perfuse renal allograft.

In conclusion, this case report demonstrates the suitability of extra-anatomical cross-over femoro-femoral bypass where other minimally invasive methods such as angioplasty fail, and there is a high risk of reoperation surgery. We, therefore, believe that it is a valuable alternative to classic aorto-iliac reconstruction in patients with jeopardized renal allografts.

Declaration of conflicting interests

The authors declared no conflicts of interest with respect to the authorship and/or publication of this article.

Funding

The authors received no financial support for the research and/or authorship of this article.

REFERENCES

1. Agüera Fernández LG, Zudaire JJ, Isa WA, Sánchez de la Muela PL, Rosell D, de Castro F, et al. Vascular complications in 237 recipients of renal transplant from cadaver. *Actas Urol Esp* 1992;16:292-5. [Abstract]
2. Merkus JW, van Asten WN, Hoitsma AJ, Buskens FG, Koene RA, Skotnicki SH. Iliac artery stenosis after kidney transplantation. *Acta Chir Belg* 1993;93:242-8.
3. Mulasari AS, Umesan CV, Radhakrishnan N, Lakshmi V. Iliac artery stenosis causing post-renal transplant hypertension: successful management by percutaneous angioplasty and stent implantation. *J Invasive Cardiol* 2002;14:212-3.
4. Whelton PK, Russell RP, Harrington DP, Williams GM, Walker WG. Hypertension following renal transplantation. Causative factors and therapeutic implications. *JAMA* 1979;241:1128-31.

5. Roberts JP, Ascher NL, Fryd DS, Hunter DW, Dunn DL, Payne WD, et al. Transplant renal artery stenosis. *Transplantation* 1989;48:580-3.
6. Weigle JB. Iliac artery stenosis causing renal allograft-mediated hypertension: angiographic diagnosis and treatment. *AJR Am J Roentgenol* 1991;157:513-5.
7. Orons PD, Zajko AB. Angiography and interventional aspects of renal transplantation. *Radiol Clin North Am* 1995;33:461-71.
8. Freeman NE, Leeds FH. Operations on large arteries; application of recent advances. *Calif Med* 1952;77:229-33.
9. Erdogan A, Ayten A, Aslaner O, Demircan A. Extra-anatomic bypasses; early and midterm results. *Damar Cer Derg* 2004;13:1-6.
10. Manduz S, Berkan O, Cetin H, Katrancioglu N, Tunel A, Dogan K. Extra -anatomic by-pass procedures. *Damar Cer Derg* 2005;14:19-24.
11. Sieńko J, Teichman K, Cnotliwy M, Falkowski A, Nowacki M, Ostrowski M. Crossed bypass femoro-femoralis in patient with external iliac artery occlusion in the course of septic hemorrhage after renal graft explantation. *Ann Transplant* 2006;11:12-4.
12. El-Harakeh MA, Barbari A, Stephan A, Saggi S, Kilany H, Barakeh A. A transplanted kidney surviving total vessel occlusion and anuria. *Clin Nephrol* 2005;64:159-62.