

A rare case of dual true aneurysms of unilateral popliteal artery

Levent Altınay , Elif Coşkun , Anıl Tekin , Ufuk Tütün 

Department of Cardiovascular Surgery, Bülent Ecevit University Faculty of Medicine, Zonguldak, Turkey

ABSTRACT

Popliteal artery aneurysm is the most common form of arterial aneurysms in the peripheral arterial system. An 86-year-old male patient with dual true aneurysms in the unilateral popliteal artery presented with leg pain without any ischemic physical signs. A proximal 20.1×17.9-mm saccular aneurysm was treated with a 9×100-mm endovascular stent graft, and a distal 50.6×54.2-mm fusiform aneurysm was treated with a 10×100-mm endovascular stent graft. In conclusion, although surgical treatment is the gold standard, endovascular treatment should be considered as an alternative method with several benefits in high-risk patients.

Keywords: Angiography, arterial aneurysms, atherosclerosis, peripheral artery disease, vascular imaging.

Popliteal artery aneurysm (PAA) is the most common form of arterial aneurysms in the peripheral arterial system. Bilateral PAAs have been reported in the literature with a rate of 50 to 70%.^[1] However, there is no case available regarding true dual aneurysms of the unilateral popliteal artery. Although surgical treatment is accepted as the gold standard, endovascular repair is also an optional treatment method in high-risk patients.^[2] Herein, we represent a case of true dual PAAs which were successfully repaired with endovascular intervention.

CASE REPORT

An 86-year-old male patient presented with right leg pain. He was previously diagnosed with right PAA as assessed by magnetic resonance angiography (MRA). He had coronary artery disease, diabetes mellitus, and hypertension and he was on medical treatment. He had no tobacco smoking habit or alcohol abuse. In his laboratory findings, blood glucose level was 182 mg/dL, erythrocyte sedimentation rate was 62 mm/h, and C-reactive protein was 42.35 mg/L. On his physical examination, both lower extremity distal arterial pulses were palpable, ankle-brachial index

was 0.76, and no skin color or temperature changes or edema were observed. The patient was consulted with a dermatologist and ophthalmologist and no diagnostic signs of Behçet's disease were found. In addition, thoracic and abdominal computed tomography (CT) angiography revealed no other arterial aneurysms. The patient was scheduled for endovascular treatment procedure. A written informed consent was obtained from the patient.

Under local anesthesia, the right femoral artery was cannulated with a 10 French (F) introducing sheath and right lower extremity angiography was performed after proper heparin dose. Two aneurysms in the popliteal artery were observed. The first 20.1×17.9-mm saccular aneurysm was located in the proximal segment of the popliteal artery and the second fusiform 50.6×54.2-mm aneurysm was located in the distal segment (Figure 1). A 9×60-mm stent graft (FLUENCY plus, Angiomed GmbH & Co. Medizintechnik KG, Karlsruhe, Germany) was applied to cover the saccular aneurysm and a 10×100-mm stent graft (FLUENCY plus, Angiomed GmbH & Co. Medizintechnik KG, Karlsruhe, Germany) was applied to the fusiform

Received: November 10, 2018 Accepted: January 23, 2019 Published online: March 08, 2019

Correspondence: Levent Altınay, MD. Bülent Ecevit Üniversitesi Tıp Fakültesi Kalp ve Damar Cerrahisi Anabilim Dalı, 67600 Kozlu, Zonguldak, Turkey.
e-mail: laltinay@gmail.com

Citation:

Altınay L, Coşkun E, Tekin A, Tütün U. A rare case of dual true aneurysms of unilateral popliteal artery. Turk J Vasc Surg 2019;28(2):127-129

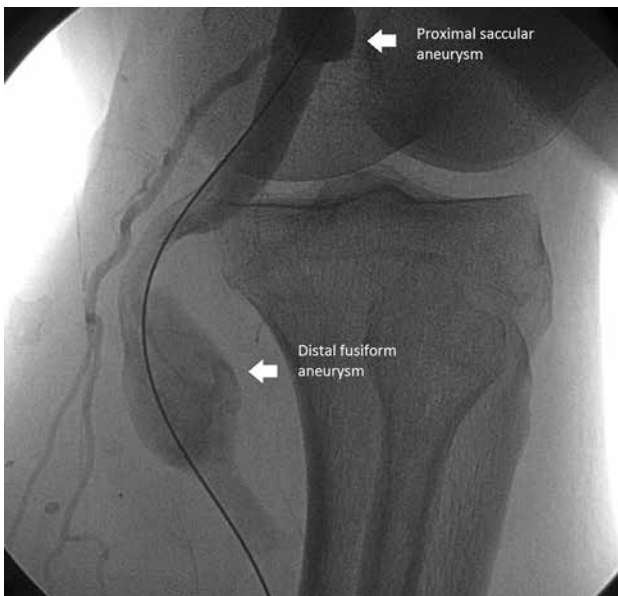

Figure 1. An intraoperative angiographic image of proximal and distal aneurysms of popliteal artery.

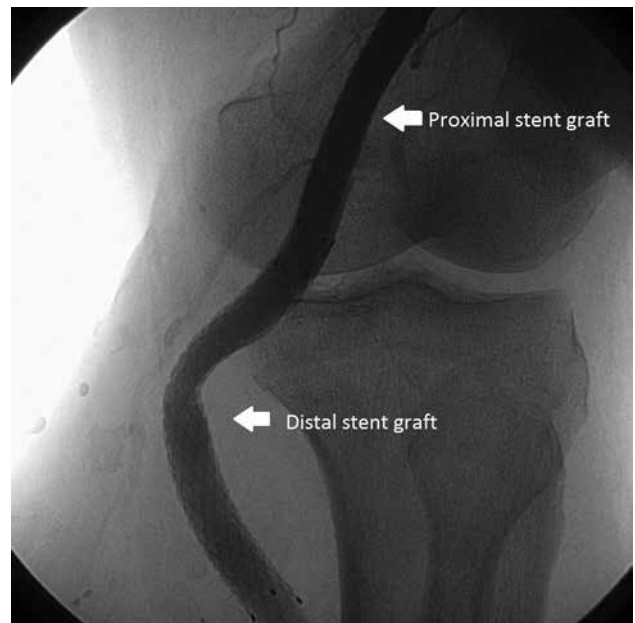


Figure 2. Postoperative control angiography of two stent grafts.

aneurysm (Figure 2). A loading dose of 300 mg oral clopidogrel was administered. The patient was discharged on the postoperative third day after an uneventful follow-up period with oral clopidogrel 75 mg tablet once a day in addition to his preoperative medications. The patient had no vascular complaints and his physical examination was normal at three months of follow-up.

DISCUSSION

The prevalence of the PAAs is reported to be approximately 1% in the general population.^[1] Most PAAs are asymptomatic and complication rate is about 8% during a three-year follow-up. Most symptomatic patients present with ischemia of the lower extremity due to thrombus or embolic material occluding the popliteal artery. In this case, the patient presented with right leg pain. On his radiological examination, no arterial occlusion, stenosis or rupture of the PAA was visualized. We believe that the leg pain of the patient may be due to non-specific etiology and the PAA was diagnosed by chance.

Turkey is located in the high prevalence region of Behçet's disease which is a multisystem inflammatory process. Arterial lesions such as aneurysms and stenoses have been reported in 7 to 18% of cases with Behçet's disease.^[3] Therefore, the patient was also examined for clinical manifestations of Behçet's disease such as oral and genital ulcers, skin lesions, and vascular

involvements. No evidence for Behçet's disease was found.

Currently, open surgery is still the gold standard for treatment of PAAs. It is strongly recommended that a repair procedure should be performed in PAAs >2 cm to prevent any thromboembolic complication or extremity loss.^[4] The endovascular treatment is another option for the treatment of PAAs which can be done under local anesthesia, is less invasive, has a lower risk of bleeding and wound infection, and shortens the length of hospital stay. In their study, Ronchey et al.^[5] compared three methods of PAA repair which were endovascular repair, great saphenous vein graft interposition, and polytetrafluoroethylene graft interposition and reported no significant difference among the three groups in terms of primary and secondary patency rates. However, there are some drawbacks of this treatment such as covered stent graft fractures or kinking. Golcwehr et al.^[6] reported graft stenosis in 36% and graft fracture in 28% of endovascular repair procedures of PAAs, although they found no significant risk factor for the stent fracture and any association between the stent fracture and occlusion. In this case, we preferred the endovascular treatment method due to the existing comorbidities such as atherosclerotic coronary heart disease, hypertension, and diabetes mellitus and his advanced age.

In conclusion, we believe that endovascular treatment should be considered as an alternative

method which can be performed safely and effectively in a very short procedural time in high-risk patients and in rare extraordinary cases.

Declaration of conflicting interests

The authors declared no conflicts of interest with respect to the authorship and/or publication of this article.

Funding

The authors received no financial support for the research and/or authorship of this article.

REFERENCES

1. Wright LB, Matchett WJ, Cruz CP, James CA, Culp WC, Eidt JF, et al. Popliteal artery disease: diagnosis and treatment. *Radiographics* 2004;24:467-79.
2. Ardita V, Giaquinta A, Orrico M, Ronchey S, Veroux M, Mangialardi N, et al. Endovascular treatment of chronic occluded popliteal artery aneurysm: early and mid-term outcomes. *J Cardiovasc Surg (Torino)* 2018;59:405-11.
3. Yin H, Li S, Wang M, Hu Z, Wang J, Yao C, et al. The value of endografts in the surgical management of arterial lesions secondary to Behçet disease. *J Vasc Surg* 2017;65:471-7.
4. Şırlak M. Abdominal aort ve periferik arter anevrizmaları. In: Bozkurt K, editör. *Periferik Arter ve Ven Hastalıkları Ulasal Tedavi Kılavuzu*. İstanbul: Bayçınar Tıbbi Yayıncılık; 2016. s. 116 - 7.
5. Ronchey S, Pecoraro F, Alberti V, Serrao E, Orrico M, Lachat M, et al. Popliteal Artery Aneurysm Repair in the Endovascular Era: Fourteen-Years Single Center Experience. *Medicine (Baltimore)* 2015;9:e1130.
6. Golchehr B, Zeebregts CJ, Reijnen MMPJ, Tiellu IFJ. Long-term outcome of endovascular popliteal artery aneurysm repair. *J Vasc Surg* 2018;67:1797-804.