

The effects of dexmedetomidine against ruptured abdominal aortic aneurysm injury to myocardial tissue induced by abdominal aorta clamping

Ozan Karakiş¹, Doğuş Hemşinli¹, Levent Tümkaya², Şaban Ergene¹, Tolga Mercantepe², Adnan Yılmaz³

¹Department of Cardiovascular Surgery, Recep Tayyip Erdoğan University, Medical Faculty, Rize, Turkey

²Department of Histology and Embryology, Recep Tayyip Erdoğan University Medical Faculty, Rize, Turkey

³Department of Medical Biochemistry, Recep Tayyip Erdoğan University Medical Faculty, Rize, Turkey

ABSTRACT

Objectives: This study aims to examine the potential protective effect of the selective alpha-2 adrenergic receptor agonist dexmedetomidine (DEX) against aortic occlusion-induced myocardial injury.

Patients and methods: A total of 30 rats were randomly assigned into three groups of 10 animals each as control, ischemia+reperfusion (I/Rep), and I/Rep+DEX. In the I/Rep and I/Rep+DEX groups, after the completion of the shock stage, 60-min lower torso ischemia was induced with the application of cross-clamps to the abdominal aorta, followed by 120-min reperfusion. The I/Rep+DEX group received intraperitoneal 100 µg/kg DEX 30 min before the ischemia period.

Results: Malondialdehyde (MDA) levels in myocardial tissue increased with the application of I/Rep, while glutathione (GSH) levels decreased. We also observed swollen, degenerative, apoptotic cardiac myofibrils exhibiting caspase-3 positivity, widespread edematous areas, vascular congestion, and an increase in the heart damage scores. The MDA levels decreased with DEX administration, while the GSH levels increased. Degenerative, apoptotic cardiac myofibrils exhibiting loss of cytoplasm content, and vascular congestion also decreased.

Conclusion: Our study results suggest that DEX may have a future role in the treatment of myocardial damage occurring due to reperfusion, following ruptured abdominal aortic aneurysm surgery.

Keywords: Abdominal aortic aneurysm, dexmedetomidine, myocardium, oxidative stress, reperfusion.

Ruptured abdominal aortic aneurysm (RAAA), which quickly becomes fatal if left untreated, is one of the emergencies of vascular surgery.^[1,2] Since the majority of patients do not survive long enough to reach a cardiovascular surgery center, the overall mortality rate is estimated as 80 to 90%.^[1] The most common treatment for patients with RAAA is open surgical repair. Despite a recent increase in the number of endovascular therapeutic procedures, surgery is still the mainstay treatment, due to difficulties concerning the experience of the team and equipment in vascular centers and the anatomical characteristics

of the aneurysm. Although the surgical procedure is completed quickly and successfully in the majority of cases, surgical mortality rates are still high due to multiple organ failure (MOF) developing during postoperative intensive care follow-up.^[2] Hemorrhagic shock in the preoperative period, ischemia caused by temporary occlusion of the infrarenal abdominal aorta (iAA) during surgery, and reperfusion injury occurring with the removal of the clamp on completion of the anastomoses are all important factors in the progression to MOF.^[2,3] Free oxygen radicals (FORs) and systemic inflammatory response (SIR) occurring

Received: March 02, 2021 Accepted: March 15, 2021 Published online: March 24, 2021

Correspondence: Ozan Karakiş, MD. Recep Tayyip Erdoğan Üniversitesi Tıp Fakültesi, Kalp ve Damar Cerrahisi Anabilim Dalı, 53020 Rize, Türkiye.
e-mail: ozankar@hotmail.com

Citation:

Karakiş O, Hemşinli D, Tümkaya L, Ergene Ş, Mercantepe T, Yılmaz A. The effects of dexmedetomidine against ruptured abdominal aortic aneurysm injury to myocardial tissue induced by abdominal aorta clamping. Turk J Vasc Surg 2021;30(2):93-101

during ischemia/reperfusion (I/Rep) result in injury in distant organs, in addition to local damage, through their systemic effects.^[3]

Ischemia developing in RAAA patients results in depletion of tissue energy sources, the development of acidosis, and cell damage.^[3] The FORs further exacerbate the severity of cell damage and commence accumulating in tissues in the first minutes of reperfusion following completion of vascular repair and cross-clamp removal.^[3,4] They also lead to damage, resulting in cell death by oxidizing essential proteins, deoxyribonucleic acid (DNA), and membrane lipids. Malondialdehyde (MDA), the final product of lipid peroxidation in cells, is an important marker of oxidative damage.^[3,5] Antioxidant enzymes such as glutathione (GSH) constitute the first defense mechanism, converting FORs into less reactive species by eliminating oxidative tissue damage.^[3,4] The DNA injury resulting from oxidative stress conclude with apoptosis. Caspases, a class of proteases involved in several functions including cell differentiation, remodeling, and cell death, are highly important mediators of apoptosis. Activation of caspase-3 is particularly important in apoptosis and in progression to cell death.^[6]

Despite advances in surgical techniques, equipment, intensive care conditions, and endovascular methods over a few decades, no significant improvement has been achieved in the high mortality and morbidity rates observed in RAAA. The use of agents capable of reducing the effects of FORs and SIR in RAAA patients, particularly those with impaired tissue perfusion as a result of exposure to hemorrhagic shock, can help to prevent morbidity and mortality.^[2,3] Dexmedetomidine (DEX) is a powerful and selective alpha-2 adrenergic receptor agonist used for sedation and anesthesia. Previous studies have reported that with its anti-inflammatory and antioxidant activities, DEX reduces the deleterious effects of I/Rep in various organs.^[4,5,7-9] Distant organ damage related to I/Rep in the lungs and kidneys has previously been investigated in RAAA, although no previous studies have examined the cardiac effects of DEX. In this experimental study, we aimed to investigate I/Rep damage in rat myocardial tissue in an RAAA model and to examine the protective potential of DEX.

PATIENTS AND METHODS

This controlled, experimental study included a total of 30 male Sprague-Dawley rats weighing 257±27 g and aged four to five months. All rats were fasted before

the experiment and were allowed water only at 12 h. The study protocol was approved by the Recep Tayyip Erdoğan University, Medical Faculty, Laboratory Animal Studies Ethics Committee (No: 2018-15). All animals used in the study were treated in accordance with the criteria specified in the Guide for the Care and Use of Laboratory Animals.

The rats were randomized based on their body weight (using a table of random numbers) divided into control, ischemia + reperfusion (I/Rep) and I/Rep+DEX groups each containing 10 animals.^[10] No procedure was applied to the control group, except for midline laparotomy and aortic exploration. Shock was applied to the I/Rep and I/Rep+DEX groups for 60 min. The same groups were, then, subjected to 60 min of ischemia with vascular clamps attached to the iAA. Finally, the vascular clamps were removed and the animals were exposed to reperfusion for 120 min.^[11] A total of 30 min before ischemia, the rats in the I/Rep DEX group were administered 100 µg/kg intraperitoneal DEX in 2 mL saline solution. The rats in the I/Rep group received only an equivalent volume of saline solution.^[5,7,9,12] The rats that died during the experiment were planned to be excluded from the study. However, since no animals died during the experimental process, all rats were included in the study.

Establishment of the RAAA model

Anesthesia was administered with 50 mg/kg ketamine hydrochloride (Ketalar®, Eczacıbaşı, Turkey) and 10 mg/kg xylazine HCl (Alfazyne®, Alfasan International BV., Woerden, Holland). The rats were first immobilized in the supine position under a heating lamp. The internal jugular vein was, then, cannulated for fluid and blood replacement. The carotid artery was cannulated and connected to a monitor with an arterial line transducer set to monitor mean arterial pressure (MAP). The aortic rupture stage was simulated with shock created by a MAP of ≤50 mmHg. For this purpose, blood was collected from the carotid artery cannula into a syringe containing 500 IU of heparin (Nevparin; Mustafa-Nevzat İlaç Sanayi, Istanbul, Turkey) and, then, stored at room temperature. All rats underwent laparotomy following the shock stage. The incisions were closed once the control group had anesthetized for 4 h. Anticoagulation in the other groups was provided by intravenous administration of 250 IU heparin. After completion of the hemorrhagic shock phase, vascular clamps were attached to the iAA. A total of 60 min of ischemia was applied by simulating the aortic

repair phase. During ischemia, the blood previously collected and stored at room temperature was returned via the jugular vein cannula.^[2,11] On completion of the ischemia period, the vascular clamps were removed and the laparotomy incisions were closed. After 120 min of reperfusion, the rats in the I/Rep and I/Rep+DEX groups were sacrificed by exsanguination.^[4,5]

Biochemical analysis

Tissue homogenization: For MDA and GSH level measurements, lung tissues were first passed through phosphate buffer and then homogenized for 1 min at 30 Hertz. The supernatant portion was separated by centrifugation at 3,000 g for 15 min.^[13]

Determination of tissue MDA levels: The prepared reaction mixtures were kept in a 94°C water bath for 15 min. A colored complex was formed through reaction with thiobarbituric acid, which was, then, measured on a spectrophotometer at 532 nm. The MDA concentrations were expressed in $\mu\text{mol/g}$ tissue.^[14]

Determination of tissue GSH levels: The Ellman method was used in the measurement of myocardial tissue GSH. Briefly, 50 μL Ellman's reagent was added to a 50 μL supernatant and 200 μL 3M Na_2HPO_4 mixture. A yellow complex was obtained by the sulfhydryl groups in the tissue homogenate and the Ellman's reagent, and this was read at 412 nm on a spectrophotometer. The GSH concentrations were expressed in $\mu\text{mol/g}$ tissue.^[15]

Histopathological analysis: Myocardial tissues were first trimmed and then fixed for 48 h in 10% formalin (Sigma Aldrich, St. Louis, MO, USA). Following routine procedures, the tissue specimens were embedded in paraffin (Merck KGaA, Darmstadt, Germany), after which 4 to 5- μm sections were taken using a Leica, RM2125RT microtome (Leica Biosystems Nussloch GmbH, Nussloch, Germany). These sections were, then, stained with hematoxylin (Harris hematoxylin, Merck, KGaA, Darmstadt, Germany) and eosin (Eosin G, Merck, KGaA, Darmstadt, Germany) (H&E), and with Goldner's Masson trichrome (Merck, KGaA, Darmstadt,

Germany). The tissues were examined under a light microscope (Olympus BX51, Olympus Corp., Tokyo, Japan) and photographed with an Olympus DP71 camera (Olympus Corp., Tokyo, Japan).

Immunohistochemistry (IHC) analysis: The avidin-biotin-peroxidase method was applied to identify apoptotic cells in myocardial tissue. Tissue sections were obtained by placing 2-3- μm sections taken from the paraffin blocks onto positively-charged slides. Following deparaffinization, the sections were placed into 3% hydrogen peroxide (H_2O_2) solution for 15 min. Secondary blocking solution was next applied for 20 min. The tissues were, then, incubated with primary antibody (Caspase-3, Rabbit polyclonal, Abcam, United Kingdom), followed by secondary antibody (Goat Anti-Rabbit IgG H&L (HRP) ab205718, Abcam, United Kingdom) for 60 min. Next, the tissues were placed into diaminobenzidine chromogen (DAB Chromogen, Abcam, United Kingdom) solution for 15 min. The tissues were finally counterstained with Harris hematoxylin (Merck, KGaA, Darmstadt, Germany) and covered with sealing solution.

Semi-quantitative analysis: Myocardial tissue sections stained with H-E were examined by two histopathologists who were blinded to study treatment allocation and clinical or laboratory information. The sections were evaluated using heart damage scores (HDS) consisting of degenerative cardiac myofibrils, edematous areas, and vascular congestion (Table 1). Analysis was performed on 45 randomly selected different areas ($\times 40$ magnification) in each myocardial tissue preparation.^[16,17]

The preparations with caspase-3 antibodies were scored by two blinded histopathologists as either none (0; less than 5%), mild (1; 6-25%), moderate (2; 26-50%) or severe (3; more than 50%). Counting was performed on 45 randomly selected distinct areas ($\times 40$ magnification) in each preparation.

Statistical analysis

Statistical analysis was performed using the PASW version 18.0 software (SPSS Inc., Chicago,

Table 1. Heart Damage Score (HDS)

Findings	Score			
	0	1	2	3
	Less than (%)	Between (%)	Between (%)	More than (%)
Degenerative cardiac myofibrils	0	6-25	26-50	50
Edematous area	0	6-25	26-50	50
Vascular congestion	0	6-25	26-50	50

Table 2. Biochemical results

Groups	MDA ($\mu\text{mol/g}$ tissue)	GSH ($\mu\text{mol/g}$ tissue)
	Mean \pm SD	Mean \pm SD
Control	0.8 \pm 0.0	12.2 \pm 1.3
I/Rep	1.0 \pm 0.0 [†]	8.1 \pm 1.0 [†]
I/Rep+DEX	0.9 \pm 0.7 ^{†‡}	10.2 \pm 2.0 ^{†‡}

MDA: Malondialdehyde; GSH: Glutathione; SD: Standard deviation; I/Rep: Ischemia + reperfusion; DEX: Dexmedetomidine; One-way ANOVA, Tukey honestly significant difference test; [†] p<0.01 vs. to control group; [‡] p<0.01 vs. to I/Rep group.

IL, USA). Normality tests were carried out using the Shapiro-Wilk, Q-Q plot, Levene's tests, and Kurtosis-Skewness variables. Parametric data were analyzed using one-way analysis of variance (ANOVA) and Tukey's honestly significant difference test. Non-parametric data yielded by semi-quantitative and biochemical analyses were expressed in median and interquartile range (IQR, 25th-75th), while parametric data were expressed in mean \pm standard deviation

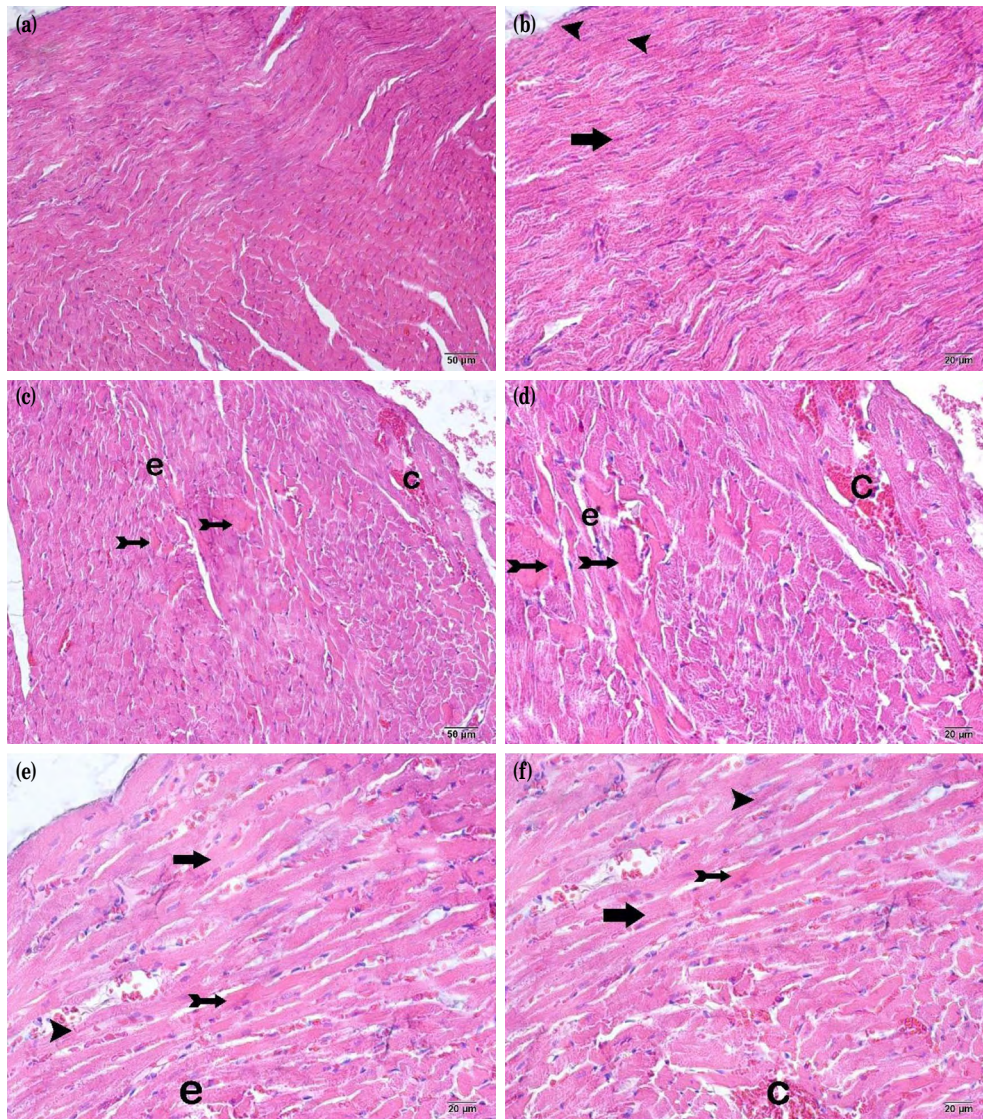


Figure 1. Representative light microscopic photographs of H-E stained heart muscle tissue. (a) ($\times 20$) (b) ($\times 40$): Cardiac myofibrils with a normal structure (arrow) and typical collateral branches (arrowhead) can be seen heart tissue sections from the control group (median HDS: 0.5 [0-1]). (c) ($\times 20$) (d) ($\times 40$): Tissue from the I/Rep group exhibits, swollen, degenerative cardiac muscle cardiac myofibrils (tailed arrow), common edematosis (e) and vascular congestion (c) (median HDS: 4 [4-5]). (e) ($\times 20$) (f) ($\times 40$): Tissue from the I/Rep+DEX group shows, a decrease in degenerative, swollen, cardiac myofibrils (tailed arrow) and vascular congestion, and (c) loss of cytoplasmic contents. In addition, cardiac myofibrils with edematosis (e) can also be seen (median HDS: 3 [3-4]).

(SD). The Kruskal-Wallis and Tamhane T2 tests were applied in the analysis of non-parametric data between the groups. A p value of <0.05 was considered statistically significant.

RESULTS

Biochemical results

The MDA levels in myocardial tissues from the I/Rep and I/Rep+DEX groups were

significantly higher than those in the control group (Table 2; $p<0.01$). The GSH levels were significantly lower in the I/Rep and I/Rep+DEX groups than in the control group (Table 2; $p<0.01$). The MDA levels were also significantly lower in the I/Rep+DEX group than in the I/Rep group, while GSH levels were significantly higher in the I/Rep+DEX group than in the I/Rep group (Table 2; $p<0.01$).

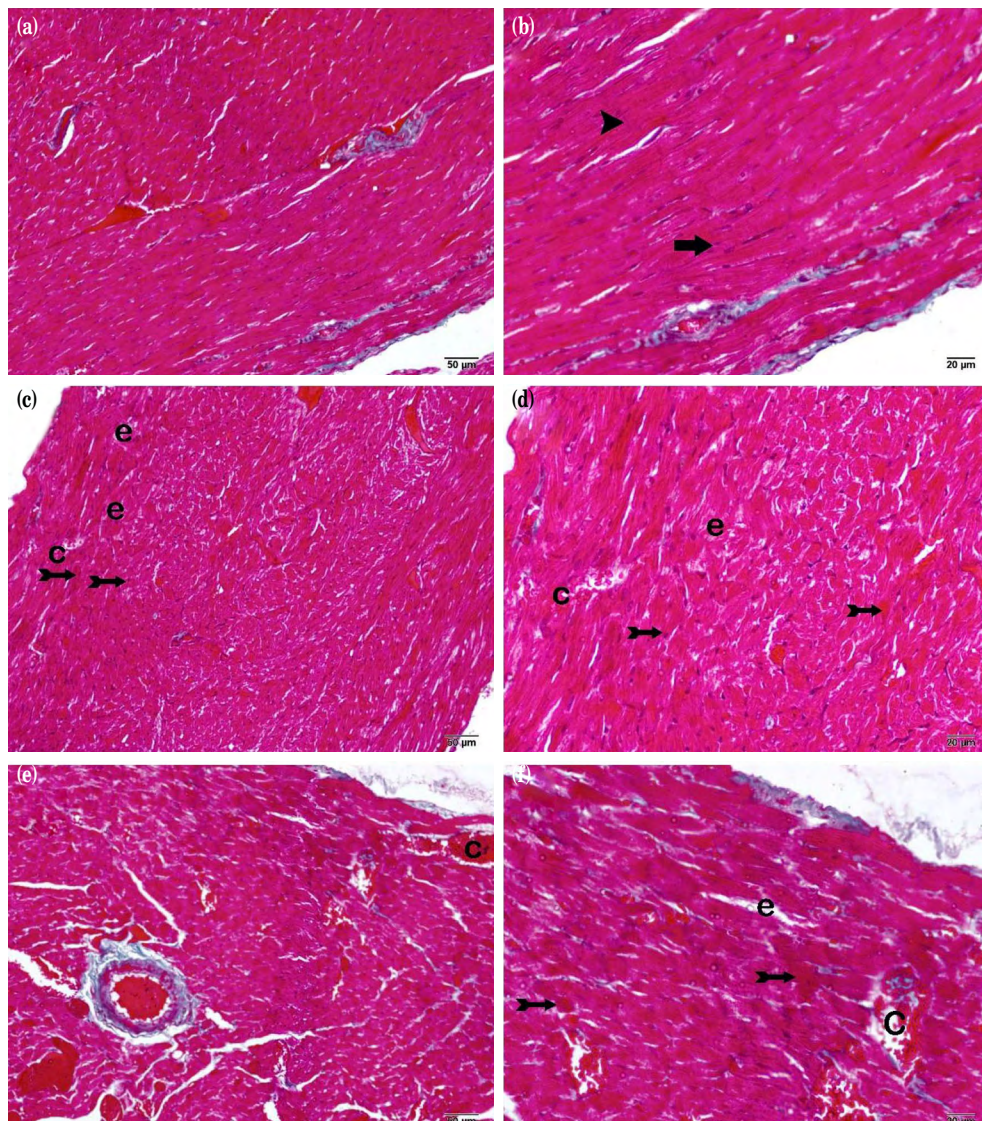


Figure 2. Representative light microscopic photographs of heart muscle tissue stained with Goldner's Masson trichrome. (a) ($\times 20$) (b) ($\times 40$): Heart tissue from the control group exhibits a normal structure. Cardiac myofibrils (arrow) and collateral branches (arrowhead) can be seen (median HDS: 0.5 [0-1]). (c) ($\times 20$) (d) ($\times 40$): Swollen, degenerative, cardiac muscle cardiac myofibrils (tailed arrow), extensive edematous areas (e) and vascular congestion (c) can be seen in heart tissue sections from the I/Rep group (median HDS: 4 [4-5]). (e) ($\times 20$) (f) ($\times 40$): A decrease in degenerative cardiac myofibrils (tailed arrow) and vascular congestion (c) can be seen in sections from the I/Rep+DEX group. Cardiac myofibrils with edematous areas (e) can also be seen (median HDS: 3 [3-4]).

Table 3. HDS results

Groups	Degenerative cardiac myofibrils		Edematous area		Vascular congestion		HDS score	
	Median	25 th -75 th IQR	Median	25 th -75 th IQR	Median	25 th -75 th IQR	Median	25 th -75 th IQR
Control	0	0-0	0	0-0	0	0-1	0.5	0-1
I/Rep	1.5 [†]	1-2	1 [†]	1-1	2 [†]	1-2	4 [†]	4-5
I/Rep+DEX	1 ^{†‡}	1-1	1 ^{†*}	1-1	1 ^{†‡}	1-1	4 ^{†‡}	3-4

HDS: Heart Damage Score; IQR: Interquartile range; I/Rep: Ischemia + Reperfusion; DEX: Dexmedetomidine; [†] p=0.001 vs. to Control group; [‡] p=0.001 vs. to I/Rep group; * p=0.725 vs. to I/Rep group; Kruskal Wallis, Tamhane T2 test.

Histopathological results

A normal cardiac myofibril architecture and a typical discus intercalaris were observed in control group myocardial tissue sections (Figures 1a, b; 2a, b; HDS median: 0.5 [0-1]). In the I/Rep group, however, we observed swollen and degenerative cardiac myofibrils, widespread edematous areas, and vascular congestion (Figures 1c, d; 2c, d; HDS median: 4 [4-5]). In the I/Rep+DEX group, in addition to edematous areas, we observed fewer swollen, degenerative cardiac myofibrils with loss of cytoplasm contents and less vascular congestion, compared to the I/Rep group (Figure 1e, f; 2e, f; HDS median: 3 [3-4]).

Semi-quantitative results

Increased degenerative cardiac myofibrils, edematous areas, vascular congestion, and HDS were observed in the I/Rep and I/Rep+DEX groups, compared to the control group (Figures 1, 2; Table 3; p=0.001). However, degenerative cardiac myofibrils and vascular congestion decreased in the I/Rep+DEX group, compared to the I/Rep group (Figures 1, 2; Table 3; p=0.001 for both).

IHC results

Cardiac myofibrils in myocardial tissue sections from the control group exhibited a normal architecture (Figure 3a; Table 4; caspase-3 positivity score median: 0.00 [0-0]). However, apoptotic cardiac myofibrils exhibiting caspase-3 positivity increased significantly in the I/Rep group, compared to the

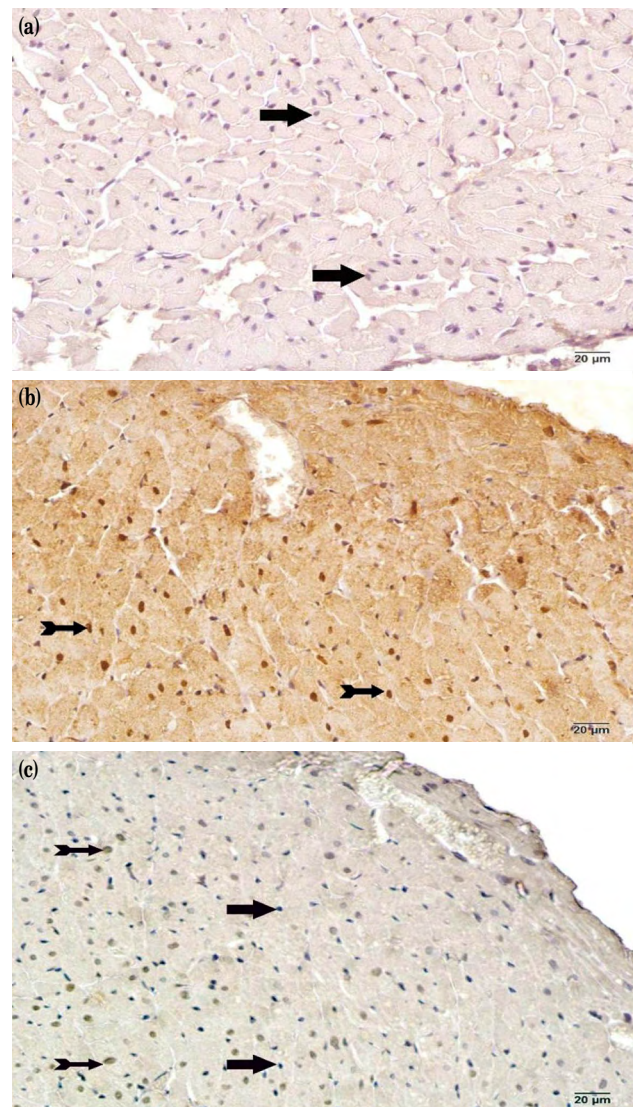


Figure 3. Representative light microscopic image of heart tissue sections with caspase-3 primary antibody and stained with immunoperoxidase. (a) (×40); Cardiac myofibrils (arrow) with a normal structure can be seen in heart tissue sections from the control group (median caspase-3 positivity score: 0.00 [0-0]). (b) (×40): Apoptotic cardiac myofibrils (tailed arrow) showing caspase-3 positivity can be seen in the I/Rep group (median caspase-3 positivity score: 2 [2-3]). (c) (×40): Tissue sections from the I/Rep+DEX group exhibit, typical cardiac myofibrils (arrow), as well as apoptotic cardiac myofibrils (tailed arrow) (median caspase-3 positivity score: 1 [1-1]).

Table 4. Caspase-3 positivity score results

Groups	Score	
	Median	25 th -75 th IQR
Control	0	0-0
I/Rep	2 [†]	2-3
I/Rep+DEX	1 ^{†‡}	1-1

IQR: Interquartile range; I/Rep: Ischemia+reperfusion; DEX: Dexmedetomidine; [†] p=0.001 vs. to Control group; [‡] p=0.001 vs. to I/Rep group; Kruskal Wallis, Tamhane T2 test.

control group (Figure 3b; Table 4; median caspase-3 positivity score: 2 [2-3]; $p=0.001$). Apoptotic cardiac myofibrils exhibiting caspase-3 positivity decreased significantly in the I/Rep+DEX group, compared to the control group, and cardiac myofibrils exhibited normal structures (Figure 3c; Table 4; mean caspase-3 positivity score: 1 [1-1]; $p=0.001$).

DISCUSSION

Halting the flow of blood to the lower half of the body during RAAA surgery through the application of cross-clamps to the iAA initiates an ischemic process. Removing the clamp once the repair has been completed and establishing sudden restoration of circulation leads to rapid re-oxygenation of ischemic tissues and I/Rep injury (IRI).^[18] Although the lower extremities, which are directly affected by the obstruction of blood flow, may appear to be the main target of IRI, simultaneous damage has also been shown to occur in distant organs such as the heart. The IRI developing following RAAA repair is associated with the increased incidence of myocardial infarction, postoperative stroke, and acute kidney injury.^[19] Cardiac complications developing due to IRI not only adversely affect the postoperative intensive care follow-up outcomes, but are also associated with a significantly increased long-term risk of cardiovascular mortality.^[18] The number of studies investigating distant organ damage caused by IRI in the myocardium as a result of iAA clamping is very limited and the molecular events underlying IRI in myocardial tissue are still unclear.^[18,19]

Once the arterial blood flow is obstructed, the balance between the metabolic requirements of the tissue and the meeting of these requirements is compromised. During reperfusion, inflammatory mediators accumulate in the ischemic tissue, and significant quantities of FORs are produced, stimulating a long-term process of cell damage.^[12,19] Organ dysfunction occurring as a result of cell damage is associated with the increased microvascular permeability, interstitial edema, parenchymal cell dysfunction, and necrosis.^[3,18] The FORs frequently involved in reperfusion injury include hydroxyl radicals, H_2O_2 , and superoxide radicals. Cardiac dysfunction developing following RAAA repair has been linked to FORs damaging structural proteins in the cell and DNA and causing lipid peroxidation in the cell membrane.^[3,12,18] Elevated tissue levels of MDA indicate the presence of oxidative stress. Enzymes such as superoxide dismutase (SOD), catalase (CAT),

and GSH are antioxidant enzymes that serve to eradicate FORs.^[3,18] Oyar et al.^[18] observed that CAT and SOD levels increased significantly, in addition to MDA, in myocardial tissues of rats subjected to IRI induced by clamping the iAA. Findik et al.^[3] reported that MDA levels increased significantly, while GSH levels decreased, in both lung and myocardial tissues of rats with IRI induced in the same manner. In the present study, MDA, the final product of phospholipid peroxidation, increased significantly in the myocardial tissues of rats with IRI induced by iAA clamping, while the levels of the antioxidant enzyme GSH decreased significantly.

In their study, Findik et al.^[3] reported disruption, a fragmented appearance, and increased interfibrillar distance in the cardiac myofibrils of rats with IRI induced by iAA clamping, together with heterogeneity in sarcoplasm. Geldi et al.^[20] similarly observed myofibrillar swelling, thick, focal hemorrhage, and polymorphonuclear leukocyte infiltration in rats with IRI induced in the same way. Gedik et al.^[21] observed a greater degeneration in cardiac myofibrils in an ischemic group, but found no significant difference between their study groups in terms of edema, inflammation, or congestion. Consistent with these studies, the HDS scores also increased significantly in myocardial tissues with the induction of IRI in the present study. We also observed swollen and degenerative cardiac myofibrils, widespread edematous areas, and vascular congestions.

Oxidative stress and lipid peroxidation play important roles in the apoptotic process. Among the proteases, the family of cysteine proteases known as caspases is particularly significantly involved. Apoptosis of myocardial cells is associated with caspase-3 activation. Caspase-3 is activated in the final stage of proapoptotic signal transmission, and may be a potential therapeutic target for the suppression of apoptosis in myocardial cells.^[18] Studies have shown that IRI induces apoptosis in the myocardium. In addition, suppression of caspase-3 activity has been shown to reduce apoptosis in myocardial cells.^[18,22] The number of studies examining distant damage caused by IRI in myocardial tissue with clamping of the abdominal aorta is still limited. Oyar et al.^[18] reported that IRI increased tumor necrosis factor- α (TNF- α) and troponin-I, in addition to caspase-3 immunoreactivity, in myocardial tissue. Du et al.^[22] induced localized ischemia by occluding the left anterior descending (LAD) artery and reported increased apoptosis rates and caspase-3 expression in infarcted myocardial cells. In the present study, in which IRI was induced

in myocardial tissue by clamping the iAA, apoptotic cardiac myofibril numbers and caspase-3 positivity also increased significantly.

Dexmedetomidine is a selective alpha-2 adrenoceptor used for anesthesia, analgesia, and sedation.^[5,7,9,12] Studies have shown that, through its anti-inflammatory and antioxidant properties, it exhibits a protective effect against IRI in organs, such as the heart, kidney, and testis.^[4,5,9] Researches have also reported that DEX reduces oxidative stress and can protect the myocardium against IRI.^[7,8] Although studies have investigated the effects of DEX against IRI induced in various tissues, to the best of our knowledge, no previous research has examined its effects against distant organ damage in the myocardium caused by cross-clamping of the iAA.^[4,5,7,9,12] Chang et al.^[7] observed that DEX significantly reduced myocardial injury induced by local IRI with LAD occlusion, increased SOD levels by lowering MDA concentrations, and suppressed caspase-3 protein expression and apoptosis. The authors concluded that DEX was able to protect the myocardium against IRI-derived apoptosis by activating the PI3K/Akt pathway in association with alpha-2 adrenoceptors. Similarly, Zhang et al.^[8] concluded that DEX reduced MDA levels, while increasing those of SOD, CAT and GSH, and suppressing apoptosis in myocardial tissue with induced local IRI. The authors observed that TNF- α and interleukin-6 levels decreased significantly following DEX administration and concluded that, owing to its protective effect on the myocardium, DEX can also restore the reduced cardiac functions occurring due to IRI. Şahin et al.^[5] also reported that DEX reduced MDA levels, while increasing those of GSH and found that it inhibited the inflammatory response, and reduced cytokine production and neutrophil infiltration, together with histopathological injury findings such as edema, bleeding and necrosis in hepatic tissue in which IRI was induced by clamping the hepatic artery. In another study, Wu et al.^[23] demonstrated that DEX played a protective role in myocardial I/Rep damage and alleviated oxidative stress and cell apoptosis by increasing GSH and decreasing MDA. In the present study, which examined distant organ damage in myocardial tissue exposed to IRI by clamping the iAA, DEX increased GSH levels that declined due to IRI, while lowering increased MDA levels. It also lowered HDS values in myocardial tissue, and reduced the numbers of cardiac myofibrils with degenerative structures and loss of cytoplasm content and exhibiting caspase-3 activity, as well as vascular congestion.

We believe that our findings are important as the first investigation of damage caused in the myocardium, a distant organ, by IRI resulting from iAA cross-clamping. On the other hand, the main limitation of this study is that we were unable to examine IRI formation in myocardial tissue with other proinflammatory cytokines, antioxidant enzymes and proteins due to budgetary constraints. Further studies in which these agents are included would further enhance the value of the present findings.

In conclusion, abdominal aortas can be successfully and quickly repaired with surgical intervention in a significant proportion of patients scheduled for emergency surgery due to RAAA, and patients can, then, be transferred to intensive care uneventfully. Multiple organ failure may develop, in such a way as to also involve myocardial damage, in association with IRI at postoperative intensive care follow-up. Cardiac function disorders developing in association with IRI are direct causes of morbidity and mortality. The identification of a specific agent capable of reducing distant organ damage caused by IRI in the myocardium is, therefore, of critical importance in terms of complication prevention. Our findings show that DEX exhibits protective effects against IRI in the myocardium caused by cross-clamping of the iAA. These results suggest that DEX may have an important future role in the treatment of myocardial damage and cardiac function disorders developing due to IRI after RAAA surgery.

Declaration of conflicting interests

The authors declared no conflicts of interest with respect to the authorship and/or publication of this article.

Funding

The authors received no financial support for the research and/or authorship of this article.

REFERENCES

1. Robinson WP. Open versus endovascular repair of ruptured abdominal aortic aneurysms: What have we learned after more than 2 decades of ruptured endovascular aneurysm repair? *Surgery* 2017;162:1207-18.
2. Altun G, Cakiroglu Y, Pulathan Z, Yulug E, Mentese A. Renoprotective potential of exogen erythropoietin on experimental ruptured abdominal aortic aneurysm model: An animal study. *Iran J Basic Med Sci* 2020;23:271-6.
3. Findik O, Kunt AT, Yazir Y, Yardimoğlu M, Yilmaz SG, Aydin U, et al. Ticagrelor attenuates apoptosis of lung and myocardial cells induced by abdominal aorta ischemia/reperfusion. *In Vivo* 2016;30:243-9.

4. Dong X, Xing Q, Li Y, Han X, Sun L. Dexmedetomidine protects against ischemia-reperfusion injury in rat skeletal muscle. *J Surg Res* 2014;186:240-5.
5. Sahin T, Begeç Z, Toprak Hİ, Polat A, Vardi N, Yücel A, et al. The effects of dexmedetomidine on liver ischemia-reperfusion injury in rats. *J Surg Res* 2013;183:385-90.
6. Basaranlar G, Derin N, Kencebay Manas C, Tanriover G, Aslan M. The effects of sulfite on cPLA2, caspase-3, oxidative stress and locomotor activity in rats. *Food Chem Toxicol* 2019;123:453-8.
7. Chang JH, Jin MM, Liu JT. Dexmedetomidine pretreatment protects the heart against apoptosis in ischemia/reperfusion injury in diabetic rats by activating PI3K/Akt signaling in vivo and in vitro. *Biomed Pharmacother* 2020;127:110188.
8. Zhang J, Jiang H, Liu DH, Wang GN. Effects of dexmedetomidine on myocardial ischemia-reperfusion injury through PI3K-Akt-mTOR signaling pathway. *Eur Rev Med Pharmacol Sci* 2019;23:6736-43.
9. Kip G, Çelik A, Bilge M, Alkan M, Kiraz HA, Özer A, et al. Dexmedetomidine protects from post-myocardial ischaemia reperfusion lung damage in diabetic rats. *Libyan J Med* 2015;10:27828.
10. Charan J, Kantharia ND. How to calculate sample size in animal studies? *J Pharmacol Pharmacother* 2013;4:303-6.
11. Lindsay TF, Walker PM, Romaschin A. Acute pulmonary injury in a model of ruptured abdominal aortic aneurysm. *J Vasc Surg* 1995;22:1-8.
12. Cakir M, Polat A, Tekin S, Vardi N, Taslidere E, Duran ZR, et al. The effect of dexmedetomidine against oxidative and tubular damage induced by renal ischemia reperfusion in rats. *Ren Fail* 2015;37:704-8.
13. Tumkaya L, Yilmaz A, Akyildiz K, Mercantepe T, Yazici ZA, Yilmaz H. Prenatal effects of a 1,800-MHz electromagnetic field on rat livers. *Cells Tissues Organs* 2019;207:187-96.
14. Draper HH, Hadley M. Malondialdehyde determination as index of lipid peroxidation. *Methods Enzymol* 1990;186:421-31.
15. Ellman GL. Tissue sulfhydryl groups. *Arch Biochem Biophys* 1959;82:70-7.
16. Ye B, Chen X, Dai S, Han J, Liang X, Lin S, et al. Emodin alleviates myocardial ischemia/reperfusion injury by inhibiting gasdermin D-mediated pyroptosis in cardiomyocytes. *Drug Des Devel Ther* 2019;13:975-90.
17. Karakişi SO, Hemşinli D, Ergene Ş, Mercantepe T, Tümkaya L, Yılmaz A. The effects of whortleberry on ischemia reperfusion-induced myocardial injury in rats. *Türk Gogus Kalp Dama* 2020;28:63-9.
18. Oyar EO, Kiriş I, Gülmen S, Ceyhan BM, Cüre MC, Sütcü R, et al. Adrenomedullin attenuates aortic cross-clamping-induced myocardial injury in rats. *Am J Surg* 2011;201:226-32.
19. Karageorgiadi DM, Tsilimigras DI, Selemenakis P, Vlachou V, de Lastic AL, Rodi M, et al. Conditioning attenuates kidney and heart injury in rats following transient suprarenal occlusion of the abdominal aorta. *Sci Rep* 2020;10:5040.
20. Geldi O, Kubat E, Ünal CS, Canbaz S. Acetaminophen mitigates myocardial injury induced by lower extremity ischemia-reperfusion in rat model. *Braz J Cardiovasc Surg* 2018;33:258-64.
21. Gedik HS, Korkmaz K, Erdem H, Karakilic E, Lafci G, Ankarali H. Protective effect of heparin in the end organ ischemia/reperfusion injury of the lungs and heart. *J Cardiothorac Surg* 2012;7:123.
22. Du J, Xu Z, Zhen J, Liu J, Yang D, Zheng EL, et al. Dexmedetomidine attenuates myocardial ischemia/reperfusion injury through regulating lactate signaling cascade in mice. *Eur Rev Med Pharmacol Sci* 2019;23:3527-32.
23. Wu ZL, Davis JRJ, Zhu Y. Dexmedetomidine protects against myocardial ischemia/reperfusion injury by ameliorating oxidative stress and cell apoptosis through the Trx1-dependent Akt pathway. *Biomed Res Int* 2020;2020:8979270.