

A unilateral carotid body tumor: A report of two cases

Tek taraflı karotis cisim tümörü: İki olgu sunumu

Ahmet Ünlü¹, Ahmet Barış Durukan¹, Işıl Yıldız²

¹Department of Cardiovascular Surgery, Medical Park Uşak Hospital, Uşak, Turkey

²Department of Radiology, Acıbadem Atakent Hospital, İstanbul, Turkey

ABSTRACT

Carotid body tumors usually occur as painless mass in the neck and are quite vascular and slow-growing tumors. Diagnosis is based on Doppler ultrasound, computed tomography, magnetic resonance and angiography. Treatment is surgical resection. Cranial nerve damage, vascular injury and bleeding are the most common surgical complications. Selective tumor embolization can be performed preoperatively to reduce tumor vascularity and blood loss during resection. Herein, we report two adult cases presenting with unilateral asymptomatic masses in the neck who were diagnosed with a carotid body tumor and were treated surgically following selective embolization.

Keywords: Carotid body tumor; operative; surgical procedure; therapeutic embolization.

ÖZ

Karotis cisim tümörleri sıklıkla boyunda ağrısız kitle olarak ortaya çıkar ve oldukça vasküler yapıda ve yavaş büyüyen tümörlerdir. Tanı Doppler ultrason, bilgisayarlı tomografi, manyetik rezonans görüntüleme ve anjiyografi ile konur. Tedavi cerrahi rezeksiyondur. Kranial sinir hasarı, damar yaralanması ve kanama en sık karşılaşılan cerrahi komplikasyonlardır. Rezeksiyon sırasında tümör vaskülaritesini ve kan kaybını azaltmak amacıyla, ameliyat öncesi dönemde selektif tümör embolizasyonu yapılabilir. Bu yazıda, boyunda tek taraflı ağrısız kitle ile başvuran, karotis cisim tümörü tanısı konan ve selektif embolizasyon sonrası cerrahi olarak tedavi edilen iki erişkin olgu sunuldu.

Anahtar sözcükler: Karotis cisim tümörü; ameliyat ile ilgili; cerrahi işlem; terapötik embolizasyon.

Carotid body tumors are the most common head and neck region paragangliomas and are located on carotid bifurcation. They are rare tumors of neuroendocrine origin.^[1] These benign tumors are considered malignant due to the surrounding tissues and intracranial spread. The first-line treatment of carotid body tumors which occur as slowly-growing masses in the neck is surgical resection.^[2] The definitive diagnosis is based on computed tomography (CT) and magnetic resonance imaging (MRI). Due to its intense vascular structure, there may be serious bleeding during the removal of the tumor. Vascular and cranial nerve damage due to dissection and retraction can be also seen.

^[3] Preoperative embolization is an effective method to reduce tumor vascularity and size. Herein, we report two adult cases who were treated surgically following selective embolization with the diagnosis of a unilateral carotid body tumor and discuss the effects of tumor embolization on surgery.

CASE REPORT

Case 1- A 57-year-old male patient was admitted due to swelling on the right side of the neck. On physical examination, a still painless mass was detected in a diameter of 4×4 cm in the mid lower third of the right

Received: August 19, 2018 Accepted: September 24, 2018

Correspondence: Ahmet Barış Durukan, MD. Medical Park Uşak Hastanesi Kalp ve Damar Cerrahisi Bölümü, 64200 Uşak, Turkey.
e-mail: barisdurukan@yahoo.com

Citation:

Ünlü A, Durukan AB, Yıldız I. A unilateral carotid body tumor: A report of two cases. Damar Cer Derg 2019;28(x):i-iv.

sternocleidomastoid muscle. Carotid CT angiography revealed a vascularized mass in the right carotid bifurcation 6×5 cm in size surrounding the right common, internal and external carotid arteries (Figure 1a). A written informed consent was obtained from the patient. Selective tumor embolization was performed before resection (Figure 1b, c). Subsequently, under general anesthesia, the mass was removed surgically in the subadventitial plane (Figure 1d-f). Neither bleeding nor neurological complications developed perioperatively. No tumor recurrence was found on carotid CT angiography in the postoperative sixth month.

Case 2- A 64-year-old woman presented with complaints of swelling on the left side of the neck. Physical examination revealed a painless, horizontally moving mass with dimensions of 4×4 cm in the lower third of the left sternocleidomastoid muscle. Ear, nose, and throat examination was performed and a 4×4 cm mass in the left carotid bifurcation surrounding the vascular structures was detected on cervical MRI. The patient was, then, referred to the cardiovascular surgery department. Carotid CT angiography revealed a mass with vascularization surrounding the common, internal, and external carotid arteries (Figure 2a). A written informed consent was obtained from the patient. Preoperative selective tumor embolization was performed before resection (Figure 2b, c). Under

general anesthesia, the mass was removed surgically in the subadventitial plane (Figure 2d-f). The patient was discharged on the postoperative Day 3 without any complication.

DISCUSSION

The most recommended surgical method in the treatment of carotid body tumors is subadventitial resection and is affected mainly by the tumor's relation with the carotid arteries. Shamblin classification frequently used to define the pathology is based on its relation with the carotid arteries.^[3] In Type 1, the tumor is in close proximity to the vessels. In Type 2, the carotid arteries are partially wrapped. In Type 3, the vessels are totally wrapped by the tumor. The first two are easier to remove from the vascular and neural structures, while the other may require vascular reconstruction.^[3] In all, however, surgical intervention should be performed by an experienced surgeon who is familiar with all surgical procedures. In both cases presented herein, the internal and external carotid arteries were almost completely wrapped with the tumor, although there was no invasion to the arterial wall. Therefore, they were accepted to be Shamblin Class 2, and there was no need for graft interposition or arterial reconstruction. In such cases, subadventitial dissection can be carefully made without harming carotid arteries.

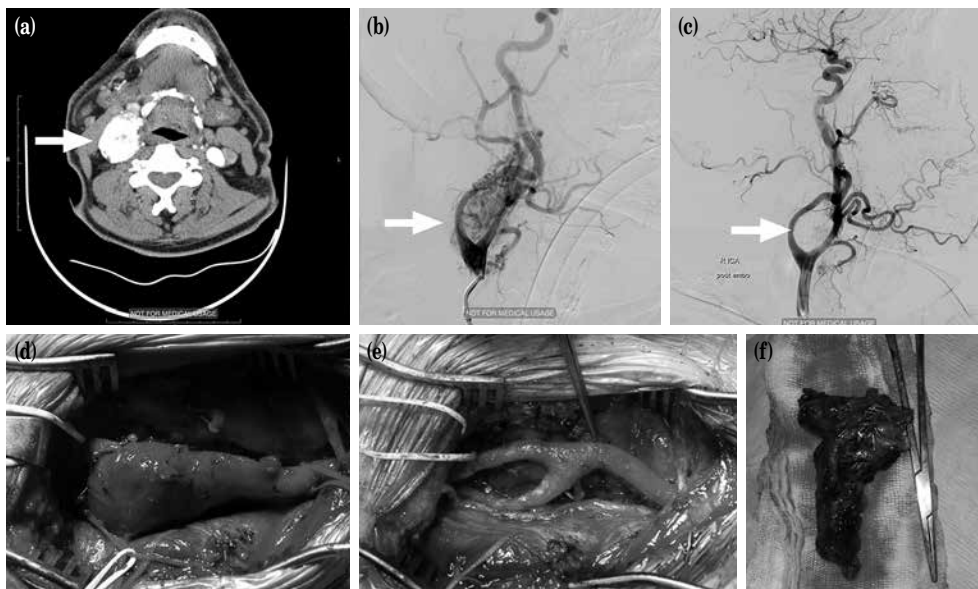


Figure 1. (a) A vascularized mass with a diameter of 5×6 cm on computed tomography angiography surrounding right common, internal, and external carotid arteries. (b) Preoperative angiographic view prior to surgical embolization. (c) Preoperative angiographic view following surgical embolization. (d) Intraoperative view of carotid body tumor prior to resection. (e) Intraoperative view of carotid arteries following resection. (f) Intraoperative resected carotid body tumor.

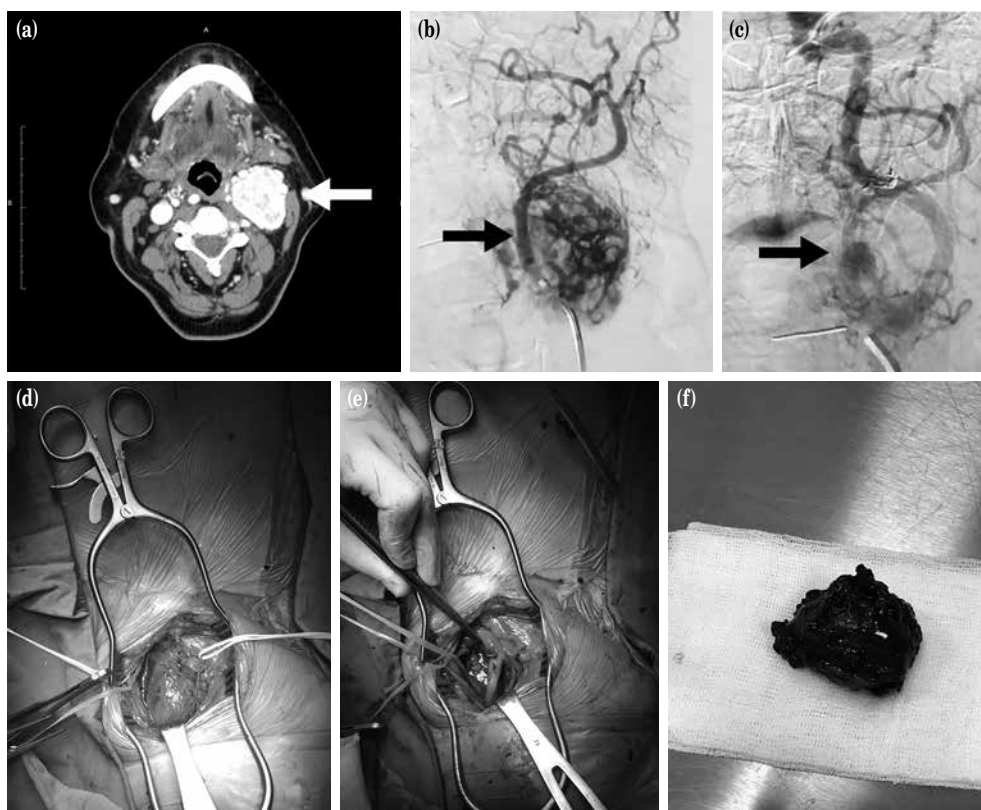


Figure 2. (a) A vascularized mass with a diameter of 4×4 cm on computed tomography angiography surrounding left common, internal, and external carotid arteries. (b) Preoperative angiographic view prior to surgical embolization. (c) Preoperative angiographic view following surgical embolization. (d) Intraoperative view of carotid body tumor prior to resection. (e) Intraoperative view of carotid arteries following resection. (f) Intraoperative resected carotid body tumor.

Embolization of carotid body tumors has become an important aid in the treatment of these tumors. The main indications of tumor embolization are to control the nourishing arteries which cannot be reached surgically, to decrease surgical morbidity by reducing blood loss, to shorten the operation time, to prepare the ground for complete surgical resection, to reduce the risk of damage to the adjacent tissues, and to provide a better vision in the surgical field.^[1] Although a clear guide is not defined, it is usually applied in large diameter (>3 cm) or Shamblin Type 2 and Type 3 tumors.^[1,4] In a systematic review of 465 patients, it was reported that embolization facilitated excision and shortened duration of surgery with reduced blood loss. The low amount of hemorrhage facilitates excision and allows complete resection, reducing the risk of recurrences. The time from preoperative embolization to surgery should be a maximum of 48 hours. Similarly, in our cases, we performed surgery within 48 hours following embolization. Both of our cases were accepted as

Shamblin Class 2; therefore, we performed selective tumor embolization prior to surgical resection to reduce intraoperative bleeding and to make the excision comfortable without leaving a residual tumor.

In addition to studies reporting reduction in intraoperative bleeding, easy excision, and improvement in surgical outcomes, there are also studies showing no statistically significant different results. A comprehensive study by Cobb et al.^[5] found no improvement in perioperative morbidity and mortality in carotid body tumors with preoperative embolization. An increase was observed in the embolization group in terms of bleeding and neurological complications.^[5] In a series of 96 patients, it was documented that embolization performed approximately in half of the patients, did not cause a statistically significant difference in terms of operative time, blood loss, vascular reconstruction requirement, and postoperative nerve deficits.^[6] Despite these studies opposing embolization, the necessity of questioning the use of embolization in

terms of cost and benefit in the treatment of carotid body tumors arises.

In conclusion, although it is evident that more comprehensive, prospective studies on the use of selective tumor embolization in carotid body tumors are needed, a thorough assessment of the vascular structure of the tumor and its Shamblin classification play a key role in the selection of patients undergoing embolization.

Acknowledgements

We would like to thank Prof. Barbaros Cil, M.D. for performing embolization in first case.

Declaration of conflicting interests

The authors declared no conflicts of interest with respect to the authorship and/or publication of this article.

Funding

The authors received no financial support for the research and/or authorship of this article.

REFERENCES

1. Abu-Ghanem S, Yehuda M, Carmel NN, Abergel A, Fliss DM. Impact of preoperative embolization on the outcomes of carotid body tumor surgery: A meta-analysis and review of the literature. *Head Neck* 2016;38:2386-94.
2. Göde S, Denli Yalvaç Ş, Talas Z, Kılıç Z, Bozkurt AK. Our surgical experience in carotid body tumors. *Damar Cer Derg* 2018;27:28-33.
3. Gür AK, Aykaç MK, Yarğı M, Eker E. Complications associated with carotid body tumor excision. *Turk Gogus Kalp Dama* 2018;26:81-5.
4. Economopoulos KP, Tzani A, Reifsnnyder T. Adjunct endovascular interventions in carotid body tumors. *J Vasc Surg* 2015;61:1081-91.
5. Cobb AN, Barkat A, Daungjaiboon W, Halandras P, Crisostomo P, Kuo PC, et al. Carotid Body Tumor Resection: Just as Safe without Preoperative Embolization. *Ann Vasc Surg* 2018;46:54-9.
6. Mourad M, Saman M, Stroman D, Brown R, Ducic Y. Evaluating the role of embolization and carotid artery sacrifice and reconstruction in the management of carotid body tumors. *Laryngoscope* 2016;126:2282-7.