

## Do we still need selective ovarian venography in diagnosis of pelvic venous disease in 2021?

Carsten Arnoldussen<sup>1,2</sup>, Marald Wikkeling<sup>3</sup>, Suat Doğançlı<sup>4</sup>

<sup>1</sup>Department of Radiology and Nuclear Medicine, Maastricht University Medical Center, The Netherlands

<sup>2</sup>Department of Radiology and Nuclear Medicine, VieCuri Medical Centre, Venlo, The Netherlands

<sup>3</sup>Heelkunde Friesland, Department of Vascular Surgery, Locations: Medical Center Leeuwarden and The Nij Smellinghe Hospital, The Netherlands

<sup>4</sup>Department of Cardiovascular Surgery, Health Sciences University, Gülhane School of Medicine, Ankara, Turkey

### ABSTRACT

Pelvic venous disease (PeVD) is an overlooked condition that can affect daily life of patients. Although medical history and physical examination may lead to suspicion of PeVD, accurate imaging is important for establishing the diagnosis with high certainty. Despite the increasing popularity of magnetic resonance imaging and Duplex ultrasound as non-invasive imaging methods, selective venography remains the gold-standard imaging method to establish the diagnosis of PeVD. In addition, venography provides an opportunity for treatment in a single procedure. In this chapter, we define the techniques for selective ovarian venography and discuss its clinical importance in diagnosis of PeVD.

**Keywords:** Diagnosis, PCS, PeVD, venography, venous.

Pelvic venous disease (PeVD) is one of a wide array of diseases in the differential diagnosis of chronic pelvic pain. Due to the broad nature of chronic pelvic pain, it is often a challenge to identify the correct underlying disease. If the cause of pelvic pain is PeVD, patients are usually treated with minimally invasive interventions. Although medical history and physical examination may lead to suspicion of PeVD, accurate imaging is important for establishing the diagnosis with high certainty. Additionally, imaging aids us in selecting the most optimal treatment options and approach.

Non-invasive imaging methods such as Duplex ultrasound (DUS), magnetic resonance imaging (MRI), and computed tomography (CT) are recommended as the first-line imaging tools in radiological examination. These imaging methods are also used to diagnose

additional pelvic pathologies associated with PeVD. Intravascular ultrasound (IVUS) and conventional venography as invasive imaging methods are often utilized in patients scheduled for an intervention. The need for IVUS to establish the diagnosis of PeVD is very rare. It is mostly applied to diagnose compressive syndromes.<sup>[1]</sup> Despite the increasing popularity of MRI and DUS, catheter-directed venography is still considered the gold-standard diagnostic test for the evaluation of PeVD.<sup>[1-6]</sup> Its major disadvantage is that it is an invasive procedure with potential risks in terms of ionizing radiation exposure, intravenous iodinated contrast, and vascular complications. An advantage is the possibility to use catheter-directed venography as an opportunity for diagnostic and therapeutic purposes in a single procedure.<sup>[7]</sup> However, we should keep in mind that without three-dimensional pre-

Received: October 07, 2021 Accepted: October 07, 2021 Published online: October 22, 2021

**Correspondence:** Carsten Arnoldussen, MD. Department of Radiology and Nuclear Medicine, VieCuri Medical Centre, 5912 BL Venlo, The Netherlands.  
e-mail: caerstens@gmail.com

### Citation:

Arnoldussen C, Wikkeling M, Doğançlı S. Do we still need selective ovarian venography in diagnosis of pelvic venous disease in 2021? Turk J Vasc Surg 2021;30(Supp. 1):S17-S21

©2021 Turkish National Vascular and Endovascular Surgery Society. All rights reserved.

This is an open access article under the terms of the Creative Commons Attribution-NonCommercial License, which permits use, distribution and reproduction in any medium, provided the original work is properly cited and is not used for commercial purposes (<http://creativecommons.org/licenses/by-nc/4.0/>).

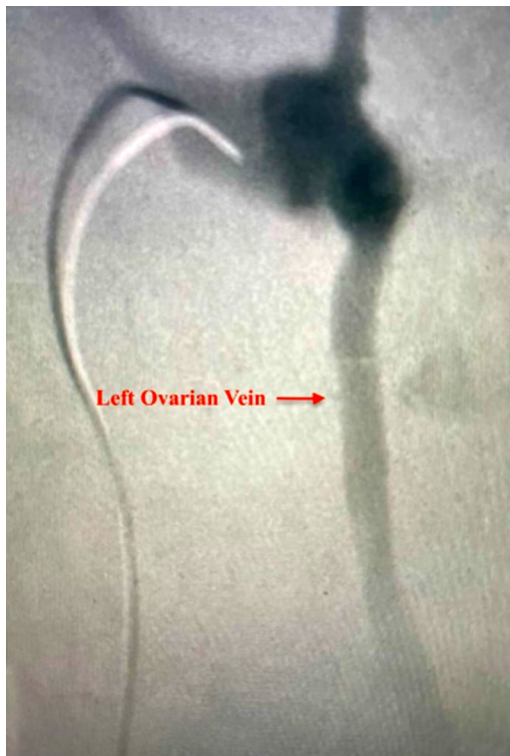


interventional imaging of the abdomen and pelvis, we are not informed about any specific anatomical variations in the patient.

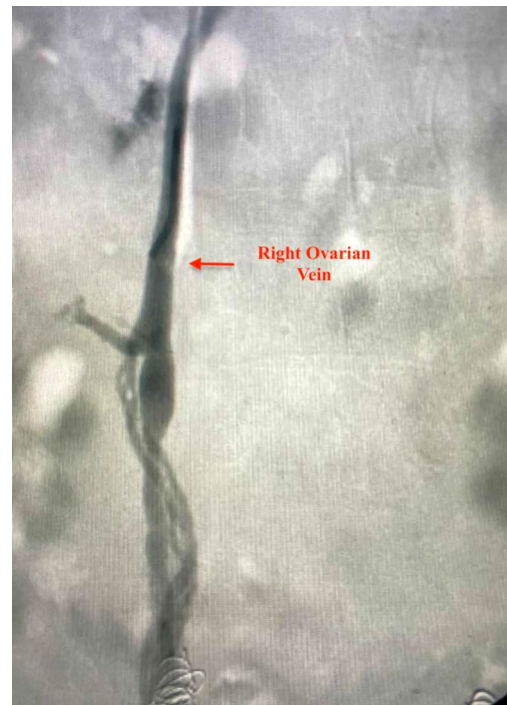## TECHNIQUE

Selective catheter-directed venography is performed percutaneously via the femoral, internal jugular or cubital vein by using an intravenous contrast medium. The study can be done under local anesthesia or/and conscious sedation. After vascular access is provided with placement of an access sheath using a direct venous puncture, the study is performed on a tilt table with the option of using fluoroscopy in various positions to obtain more dynamic flow information and measurements from the venous collection and drainage system while, if needed, changing patient position.<sup>[8,9]</sup> Selective catheterization of the ovarian and internal iliac veins is performed routinely using different types of 4F to 5F catheters, such as the Simmons I or II, Multipurpose or Cobra II, usually over hydrophilic guidewires (regular and/or stiff).<sup>[3,9]</sup> Selective catheterization allows for the use of less intravenous contrast medium than non-selective catheterization. In addition, using vertebral bony

landmarks not only facilitates catheterization, but also allows us to perform the procedure in less fluoroscopy time.<sup>[10]</sup> In a study, the lowest renal vein level was found to correspond to L1 vertebral body in 17.3%, L1-2 disc space in 36.5%, L2 vertebral body in 34.6%, L2-3 disc space in 7.7%, and L3 vertebral body in 3.8%.<sup>[10]</sup> The left gonadal vein (GV) drains into the left renal vein (Figure 1), whereas the right drains directly into the inferior vena cava (IVC) (Figure 2). The mean distance the left GV from the edge of the IVC orifice is 35 mm.<sup>[11]</sup> Its orifice was found within the first 30 mm to the left of spine in all cases.<sup>[9]</sup> The mean distance of insertion of the right GV below the ostium of the renal vein is found 18 mm, and 84% of GV were within 25 mm below the renal vein ostium.<sup>[11]</sup> It usually arises from the lateral or anterolateral wall of the IVC and can rarely originate from the right renal vein (RRV).<sup>[9]</sup> After the selective catheterization, diagnostic enhancing maneuvers such as Valsalva or elevating the head of the table can be often performed to reveal pathological reflux.<sup>[12,13]</sup> The patient should be tilted into the semi-erect position before images are taken. The same the procedure is, then, repeated for the right side.<sup>[6]</sup> The basic protocol begins with the catheterization of the left renal vein, with simultaneous



**Figure 1.** Catheterization of the left renal vein with visualization of an (incompetent) proximal left ovarian vein.



**Figure 2.** Catheterization of the right ovarian vein with after contrast injection visualization of the (dilated) right ovarian vein. Distally, we can see coils in the left and right internal iliac veins.

pressure gradient measurements to investigate for the nutcracker syndrome. The evidence for a true gradient differential over the renal vein is scarce, and it is technically difficult to execute right. However, a reno-caval pressure gradient of  $\geq 3$  mmHg is defined as renal venous hypertension.<sup>[2]</sup> Then, the catheter is moved to the left iliac vein to investigate ilio-caval pressure gradient measurement for the May-Thurner syndrome.<sup>[9]</sup> Subsequently, GVs and, finally, internal iliac veins, are investigated. The Valsalva maneuver may provide easy evaluation of the venous insufficiency and pelvic escape point determination during internal iliac vein venography.<sup>[9]</sup> Left ovarian vein insufficiency has been suggested to be assessed in three reflux grades by Hiromura et al.<sup>[14]</sup> Grade I refers to the retrograde flow confined in the left ovarian vein, not reaching to the parauterine veins; Grade II to the retrograde flow advancing into the ipsilateral parauterine veins; and Grade III to the retrograde flow crossing the midline and reaching the contralateral periuterine venous plexus or further (Figures 3-5).

Four anatomic zones of the abdomen and pelvis are defined to explain the symptoms, signs, and pathophysiological manifestations of PeVD according to a recently published classification, namely the “symptoms-varices-pathophysiology (SVP) classification system, issued by the American Vein & Lymphatic Society (AVLS) International Working Group.<sup>[15]</sup> Venography provides important information about venous anatomy, collateral venous circulation, diameter of ovarian and pelvic veins, venous incompetence, venous congestion, and retrograde filling.<sup>[16,17]</sup> It can also show the first three zones directly. Therefore, The SVP classification system requires a complete assessment of the pelvic venous anatomy and flow patterns, which mandates venography.<sup>[18]</sup>

The diagnostic criteria for pelvic congestion syndrome with venography examination are defined in the International Union of Phlebology/L'Union Internationale de Phlébologie (UIP) consensus document, as shown in Table 1.<sup>[9]</sup>

Table 1. Criteria for pelvic congestion:<sup>[9]</sup>

Ovarian vein diameter	>6 mm*
Contrast retention	>20 sec.
Congestion of pelvic venous plexus and/or opacification of the ipsilateral /contralateral internal iliac vein	Present
Filling of vulvovaginal and thigh varicosities	Present

\* As a side note, it remains important to be careful while deciding on a treatment indication on imaging, in particular vein diameter, alone.

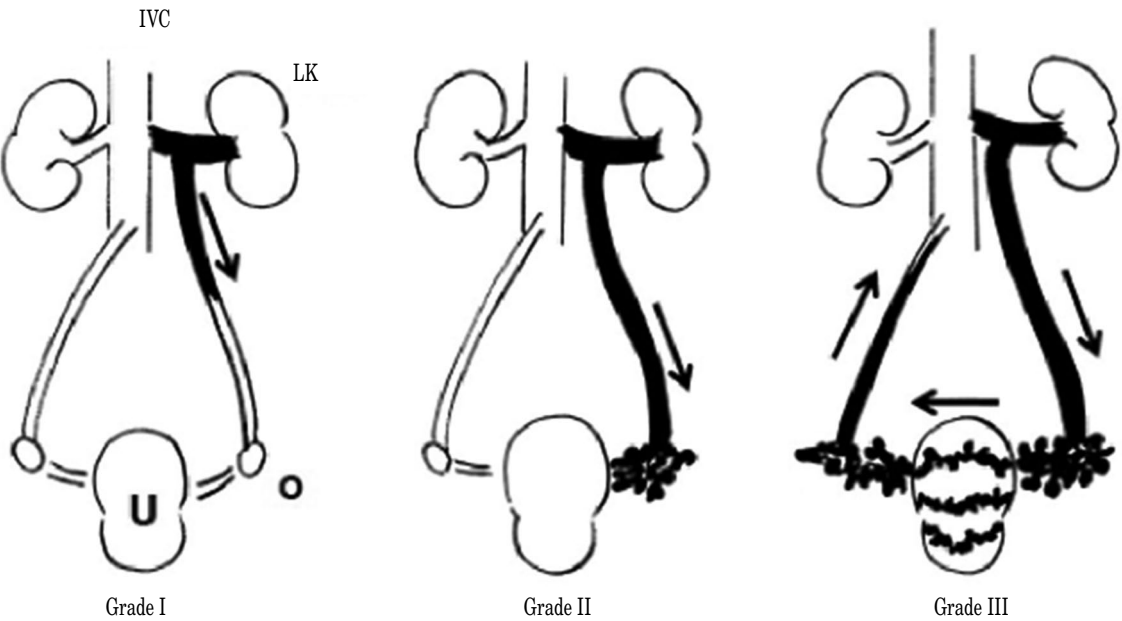
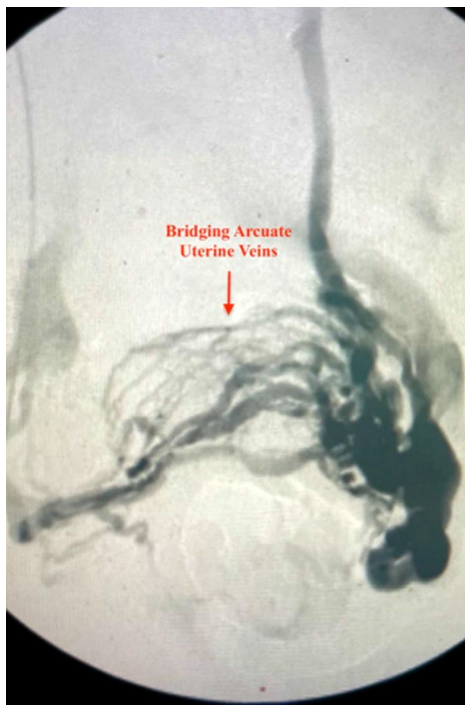
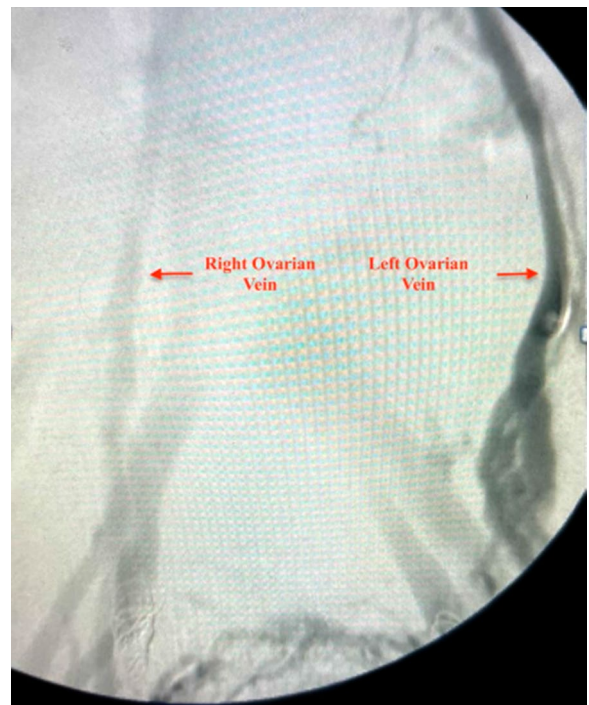
Figure 3. Image showing the grades of left ovarian vein insufficiency. IVC: Inferior vena cava; LK: Left kidney; U: Uterus; O: ovary.



**Figure 4.** Catheterization of the distal ovarian vein on the left with after contrast injection visualization of the left ovarian vein plexus, the uterine plexus and (part of) the right ovarian vein plexus. Note that there are also communicating veins to the internal iliac vein systems visible.



**Figure 5.** Catheterization of the left ovarian vein with after contrast injection filing of both the pelvic plexus (ovarian, uterine) as well as the deep iliac veins. Note the overflow of contrast from the left ovarian vein system to the right. There are some coils *in situ* distally at the level of the internal iliac veins.

Ovarian vein diameter is considered normal, if it is measured within 1 to 4 mm; moderate, 5 to 8 mm; and severe,  $\geq 8$  mm.<sup>[19]</sup> In a study, the diameter of left ovarian vein in patients with PeVD was significantly larger in symptomatic individuals, compared to healthy individuals.<sup>[20]</sup> In addition, the positive predictive value of GV insufficiency for a left ovarian vein diameter of 5 mm was found to be 71% and of 6 mm was found to be 83%.<sup>[21]</sup> Although, ovarian vein diameter is a diagnostic criteria in the UIP consensus document, it has been shown to be a poor predictor of GV reflux.<sup>[22]</sup> The aforementioned study showed a sensitivity, specificity, and accuracy of a diagnosis according to this 8-mm cut-off value of 53%, 60%, and 56%, respectively. Moreover, in an another study, PeVD symptoms did not depend on the degree of expansion of the pelvic veins.<sup>[23]</sup> Although the incidence of PeVH increased with the increased vein diameters in the recent SVP classification, the authors abstained from specifying the exact vessel diameter.<sup>[9]</sup>

In conclusion, venography is ideally performed for confirmation of diagnosis, further evaluation of the venous anatomy and collateral venous circulation, and decision making to treat and where to treat.

Although non-invasive imaging modalities provide important information about pelvic vascular and non-vascular structures, in particular anatomy, selective venography of ovarian and internal iliac veins for diagnosis of pelvic venous pathologies continues to remain the gold-standard imaging method to establish the diagnosis. Moreover, venography provides an opportunity for treatment in a single procedure. The question remains, what patients benefit the most from, a non-invasive analysis first or a (potentially diagnostic) direct intervention.

#### Declaration of conflicting interests

The authors declared no conflicts of interest with respect to the authorship and/or publication of this article.

#### Funding

The authors received no financial support for the research and/or authorship of this article.

## REFERENCES

1. Doganci S. Poorly understood pelvic venous disorders require a multidisciplinary approach. *Phlebologie* 2021;50:279-82.



2. Khilnani NM, Meissner MH, Learman LA, Gibson KD, Daniels JP, Winokur RS, et al. Research priorities in pelvic venous disorders in women: Recommendations from a multidisciplinary research consensus panel. *J Vasc Interv Radiol* 2019;30:781-9.
3. Kutsenko O, McColgan Y, Salazar G. Iliac vein stenosis: Is the data strong enough for stenting in the young pelvic venous disorders (PeVD) population? *Tech Vasc Interv Radiol* 2021;24:100733.
4. Bendek B, Afuape N, Banks E, Desai NA. Comprehensive review of pelvic congestion syndrome: Causes, symptoms, treatment options. *Curr Opin Obstet Gynecol* 2020;32:237-42.
5. Ganeshan A, Upponi S, Hon LQ, Uthappa MC, Warakaulle DR, Uberoi R. Chronic pelvic pain due to pelvic congestion syndrome: The role of diagnostic and interventional radiology. *Cardiovasc Intervent Radiol* 2007;30:1105-11.
6. Liddle AD, Davies AH. Pelvic congestion syndrome: Chronic pelvic pain caused by ovarian and internal iliac varices. *Phlebology* 2007;22:100-4.
7. Joh M, Grewal S, Gupta R. Ovarian vein embolization: How and when should it be done? *Tech Vasc Interv Radiol* 2021;24:100732.
8. Venbrux AC, Lambert DL. Embolization of the ovarian veins as a treatment for patients with chronic pelvic pain caused by pelvic venous incompetence (pelvic congestion syndrome). *Curr Opin Obstet Gynecol* 1999;11:395-9.
9. Antignani PL, Lazarashvili Z, Monedero JL, Ezpeleta SZ, Whiteley MS, Khilnani NM, et al. Diagnosis and treatment of pelvic congestion syndrome: UIP consensus document. *Int Angiol* 2019;38:265-83.
10. Danetz JS, McLafferty RB, Ayerdi J, Gruneiro LA, Ramsey DE, Hodgson KJ. Selective venography versus nonselective venography before vena cava filter placement: Evidence for more, not less. *J Vasc Surg* 2003;38:928-34.
11. Barber B, Horton A, Patel U. Anatomy of the origin of the gonadal veins on CT. *J Vasc Interv Radiol* 2012;23:211-5.
12. Borghi C, Dell'Atti L. Pelvic congestion syndrome: The current state of the literature. *Arch Gynecol Obstet* 2016;293:291-301.
13. Topper SR, Winokur RS. Imaging of pelvic venous disorders (PeVD); should every patient get an MRI? *Tech Vasc Interv Radiol* 2021;24:100731.
14. Hiromura T, Nishioka T, Nishioka S, Ikeda H, Tomita K. Reflux in the left ovarian vein: Analysis of MDCT findings in asymptomatic women. *AJR Am J Roentgenol* 2004;183:1411-5.
15. Meissner MH, Khilnani NM, Labropoulos N, Gasparis AP, Gibson K, Greiner M, et al. The Symptoms-Varices-Pathophysiology classification of pelvic venous disorders: A report of the American Vein & Lymphatic Society International Working Group on Pelvic Venous Disorders. *J Vasc Surg Venous Lymphat Disord* 2021;9:568-84.
16. Gloviczki P, Comerota AJ, Dalsing MC, Eklof BG, Gillespie DL, Gloviczki ML, et al. The care of patients with varicose veins and associated chronic venous diseases: Clinical practice guidelines of the Society for Vascular Surgery and the American Venous Forum. *J Vasc Surg* 2011;53(5 Suppl):2S-48S.
17. Lazarashvili Z, Antignani PL, Monedero JL. Pelvic congestion syndrome: Prevalence and quality of life. *Phlebology* 2016;23:123-6.
18. White JV. Unifying the concepts of pelvic venous flow disorders and noncyclic chronic pelvic pain. *J Vasc Surg Venous Lymphat Disord* 2021;9:563-4.
19. Bookwalter CA, VanBuren WM, Neisen MJ, Bjarnason H. Imaging appearance and nonsurgical management of pelvic venous congestion syndrome. *Radiographics* 2019;39:596-608.
20. Whiteley MS, Dos Santos SJ, Harrison CC, Holdstock JM, Lopez AJ. Transvaginal duplex ultrasonography appears to be the gold standard investigation for the haemodynamic evaluation of pelvic venous reflux in the ovarian and internal iliac veins in women. *Phlebology* 2015;30:706-13.
21. Park SJ, Lim JW, Ko YT, Lee DH, Yoon Y, Oh JH, et al. Diagnosis of pelvic congestion syndrome using transabdominal and transvaginal sonography. *AJR Am J Roentgenol* 2004;182:683-8.
22. Dos Santos SJ, Holdstock JM, Harrison CC, Lopez AJ, Whiteley MS. Ovarian vein diameter cannot be used as an indicator of ovarian venous reflux. *Eur J Vasc Endovasc Surg* 2015;49:90-4.
23. Gavrilo S, Moskalenko YP, Mishakina NY, Efremova OI, Kulikov VM, Grishenkova AS. Stratification of pelvic venous reflux in patients with pelvic varicose veins. *J Vasc Surg Venous Lymphat Disord* 2021:S2213-333X(21)00220-1.