

Lower Extremity Post-Traumatic Lymphedema Secondary to Accidental Injection of a Veterinary Drug: Case Report

Kaza ile Yapılan Hayvansal İlaça Bağlı Gelişmiş Posttravmatik Alt Ekstremitte Lenfödem

Murat KADAN,^a
Gökhan ARSLAN,^a
Gökhan EROL,^a
Erkan KAYA,^a
Suat DOĞANCI,^a
Cengiz BOLCAL,^a
Ufuk DEMİRKILIÇ^a

^aDepartment of Cardiovascular Surgery,
Gülhane Military Medical Academy,
Ankara

Geliş Tarihi/Received: 10.05.2014
Kabul Tarihi/Accepted: 11.06.2014

Yazışma Adresi/Correspondence:
Murat KADAN
Gülhane Military Medical Academy,
Department of Cardiovascular Surgery,
Ankara,
TÜRKİYE/TURKEY
muratkadan@yahoo.com

ABSTRACT Despite improvements in medical technologies, there is still not a holistic approach to lymphatic disorders. However, secondary lymphedema is a preventable form of lymphatic disorders by its association with the underlying etiology. Thus, it is easier to prevent than cure. In this report, we present a patient admitted to our clinic with an interesting traumatic lymphedema secondary to accidental injection of tilmicosin phosphate, which is often used as macrolide antibiotic in veterinary practice.

Key Words: Lymphedema; macrolides; necrosis; fibrosis

ÖZET Tıp teknolojilerinde yaşanan gelişmelere rağmen, halen lenfatik hastalıklar için etkin bir yaklaşım bulunmamaktadır. Bununla birlikte, sekonder lenfatik hastalıklar, altta yatan etyolojik faktörlerin önlenmesi ile önenebilir patolojilerdir. Bu yazımızda, sıklıkla veteriner hekimlikte makrolid grubu antibiyotik olarak kullanılan tilmicosin fosfat molekülünün kazara enjeksiyonu sonucu gelişmiş travmatik lenfödem tablosu ile kliniğimize başvurmuş ilginç bir vaka sunulmaktadır.

Anahtar Kelimeler: Lenfödem; makrolidler; nekroz; fibrozis

Damar Cer Derg 2015;24(2):134-7

Lymphedema is significant disorder that can be defined as abnormal accumulation of the interstitial fluid in the intracellular space. It is closely related to lymphatic and venous pathologies. Although it is more common in females, it can affect both genders.¹ This disorder can be classified into two forms, according to its etiologies. If there is not another underlying disorder, it is called as primary lymphedema, and if there is an underlying cause, it is called as secondary form.^{1,2}

Main etiologic factor of secondary lymphedema is the structural and functional change on lymphatic ducts and vessels, which are almost irreversible. For this reason, most of the secondary lymphedema cases cannot be cured even if the etiology is well known.²

Main diagnostic tools are lymphoscintigraphy and Doppler ultrasonography.³ Lymphoscintigraphy has 73-97% sensitivity with 100% specificity for lymphatic disorders. It also has a major role for the differentiation of venous disorders to lymphatic disorders. In postthrombotic venous disorder

ders, the subfacial lymphatic flow is affected while the epifacial flow is unaffected. However, in lymphatic disorders, both of these lymphatic flows are affected, thus lymphoscintigraphy can define these two entities.^{1,4}

Treatment of lymphedema includes medical treatment, mechanical treatment and surgical treatment. Preventing of the etiologic factors or its sequences are the cornerstones of prophylaxis. Several molecules such as diuretics or benzopyrones can be used for medical treatment. Surgical treatment can only be done in 5-10% of the patients. Mechanical compression therapy is the most effective approach for symptomatic relief. Compression therapy reduces edema by increasing the interstitial pressure, therefore reduces the tension of the skin. Reducing skin tension not only provides symptomatic relief, but also prevents the possible complications such as infection or concomitant thrombosis. This is why compression devices are widely used in clinical practice both for therapeutic and prophylactic purposes.³

In this report, we aimed to present an unusual case of secondary traumatic lymphedema, which developed after misinjection of a veterinary drug. The informed consent of the patient was obtained before the preparation of this paper.

CASE REPORT

A 20-year-old male patient presented to our department with swelling of his right limb. His history revealed an accidental injection to his right calf one month previously. The injected drug was tilmicosin phosphate, a macrolide antibiotic, used in the veterinary practice. The injection volume, which was not known exactly, was probably 10 ml (60 mg tilmicosin phosphate). After injection, the affected limb swelled day by day, and the patient admitted to another hospital on 20th day after injection. Compartment syndrome was diagnosed in this center, and topical corticoids, systemic flurbiprofen (100 mg twice a day) and pregabalin treatment (75 mg twice a day) were started. He was discharged from hospital nine days later without any obvious symptomatic relief. The patient was

then admitted our department with his ongoing complaints.

On physical examination, right lower limb swelling and stiffness with mild erythema, and edema near the injection area were detected (Figure 1). His right limb was 7 cm larger at the ankle, and 4 cm larger at calf level, when compared with the contralateral extremity. He had a limitation of right ankle motion. The patient had positive of Homan's sign at his right calf.

On venous Doppler ultrasonography, the deep veins were normal while chronic thrombophlebitis was detected in both great and small saphenous veins with significant subcutaneous edema. On three-phase bone scintigraphy, there was a local necrosis and heterotopic ossification area, which was probably secondary to injection or hemorrhage in gastrocnemius muscle. There were no signs of reflex sympathetic dystrophy (RSD) on bone scintigraphy. On lymphoscintigraphy, there was a delay at the distribution of the Tc-99m at the affected limb, which was concordant with lymphedema (Figure 2).

The patient was referred to immunology department for the investigation of hypersensitivity disorders. Examinations did not reveal any evidence for allergic, immunologic or rheumatologic disorders. The patient was diagnosed with acute traumatic lymphedema after all investigations.

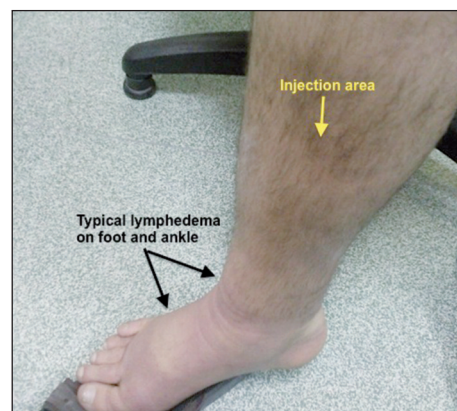


FIGURE 1: The appearance of typical lymphedema at ankle and foot with erythema at the injection site.

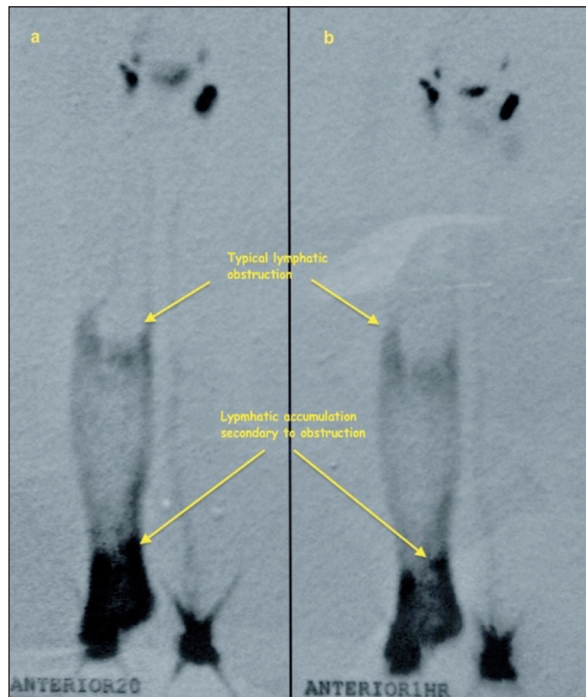


FIGURE 2: Lymphoscintigraphy of the patient. **a.** Anterior view, on 20th minute. **b.** Anterior view, at 1st hour.

Intermittent pneumatic compression therapy was started with 50 mmHg pressure, twice a day. Flurbiprofen (100 mg twice a day) and, diosmin/hesperidin combination (450/50 mg twice a day) were added to mechanical compression therapy. After 5 days, his right limb was 3 cm larger at the ankle, and 1.5 cm larger at calf level when compared with the contralateral extremity. After 30 days, there was no significant difference between the circumferences of lower extremities.

DISCUSSION

Limb swelling has deterministic effects on quality of life. Bilateral involvement is rare, and particularly seen in the primary form. However, secondary forms are much more common, and often courses unilaterally. Primary form can be separated into three subgroups; congenital (0-1 year), precox (1-35 year) and tarda (after 35 year).¹ Secondary form is associated with lymphatic obstruction secondary to several causes such as; post-inflammation, surgical procedures, infections (cellulites, erysipelas etc.), secondary fibrotic events and trauma.^{1,5}

Traumatic lymphedema is not a rare disorder in the population suffering from lymphedema. However, we cannot find any secondary forms that develop after misinjection of a drug used in veterinary practice. In our case, the molecule included tilmicosin phosphate, which is a systemic antimicrobial agent.

Tilmicosin phosphate is a subgroup of macrolides, and especially effective on gram-positive bacteria. It is a parenteral solution for cattle and sheep, and primarily shows its effect with inhibiting the protein synthesis.^{5,6} Prospectus of this agent recommends subcutaneous injection, and it is stated that an intramuscular injection must be avoided. The most important side effect of this agent is cardiotoxicity due to its negative inotropic, myocardial depression and tachycardia effects. The other side effects include local edema, sometimes necrosis and scars, particularly seen after intramuscular injections.

In our patient, there was topical edema in skin without any superficial necrosis or scar formation. However, there was a local necrosis in gastrocnemius muscle, which can be secondary to the intramuscular misinjection of this molecule. We consider that misinjection probably caused local necrosis, and a scar formation began near the necrotic area. These structural changes probably irreversibly interrupted and/or disrupted local lymphatic ducts and vessels, resulting in an impaired lymphatic flow.

Reconstructive lymphatic surgery was not suitable due to the localization of the lesion, which was so distal for such a kind of surgery. Lymphovenous shunt was also not suitable due to concomitant venous thrombophlebitis.^{7,8}

In the follow up of our patient, symptomatic relief was seen with medical therapy and compression treatment, and a surgical intervention were not preferred.

In conclusion, we consider that main cause of the lymphedema in our case was the misinjection which caused local necrosis and scar formation, rather than other factors that may cause superficial inflammation (such as erysipelas or cellulitis).

From this point of view, we conclude that misapplication of parenteral drugs by inappropriate routes, as well as to inappropriate locations, can cause severe damage to local important structures. On the other hand, secondary lymphedema should be kept in mind in patients with lym-

phedema-like leg swelling after unusual interventions.

Conflict of Interest

Authors declared no conflict of interest or financial support.

REFERENCES

1. Oz BS, Sargin M, Iyem H, Bolcal C, Mataracı I, Akay HT, Dogancı S, Tatar H. The incidence and factors influencing lymphedema in lower extremities. *Turkish J Thorac Cardiovasc Surg* 2006;14(4):304-7.
2. Rijke AM, Croft BY, Johnson RA, de Jongste AB, Camps JA. Lymphoscintigraphy and lymphedema of the lower extremities. *J Nucl Med* 1990;31(6):990-8.
3. Tiwari A, Cheng KS, Button M, Myint F, Hamilton G. Differential diagnosis, investigation, and current treatment of lower limb lymphedema. *Arch Surg* 2003;138(2):152-61.
4. Khan O, Maharaj P, Rampaul R, Archibald A, Naipaul R, Loutan N. Lymphoscintigraphic evaluation of chronic lower limb oedema. *West Indian Med J* 2003;52(2):136-9.
5. Özişik K, Aydın H. Çocukluk çağında lenfatiko-venöz şant uygulaması. *Damar Cer Derg* 2009;18(1):20-2.
6. Reuter RZ, Carroll JA, Dailey JW, Cook BJ, Galyean ML. Effects of dietary energy source and level and injection of tilmicosin phosphate on immune function in lipopolysaccharide-challenged beef steers. *J Anim Sci* 2008; 86(8):1963-76.
7. Szczesny G, Olszewski WL, Deszczynski J. [Post-traumatic lymphatic and venous drainage changes in persistent edema of lower extremities.] *Chir Narzadow Ruchu Ortop Pol* 2000;65(3):315-25.
8. Olszewski WL. The lymphovenous microsurgical shunts for treatment of lymphedema of lower limbs: indications in 2011. *Int Angiol* 2011;30(6):499-503.