

Surgical Therapy for Disseminated Arterial Involvement in Behcet's Disease: Case Report

Behçet Hastalığında Yaygın Arteriyel Tutulumun Cerrahi Tedavisi

Mehmet KALENDER,^a
Ayşe Gül KUNT,^a
Okay Güven KARACA,^a
Mehmet TAŞAR^a

^aClinic of Cardiovascular Surgery,
Konya Education and Research Hospital,
Konya

Geliş Tarihi/Received: 27.09.2012
Kabul Tarihi/Accepted: 15.04.2013

Yazışma Adresi/Correspondence:
Mehmet KALENDER
Konya Education and Research Hospital,
Clinic of Cardiovascular Surgery, Konya,
TÜRKİYE/TURKEY
ka97084@yahoo.com

ABSTRACT Surgical treatment of arterial Behcet's Disease has a higher incidence of anastomotic pseudoaneurysm or graft occlusion. A 59-year-old male patient presented with arm pain and shortness of breath. Medical history revealed Behcet's disease. Magnetic resonance imaging and computerized tomography showed aneurysms of main pulmonary, right innominate and left subclavian arteries and occlusion of bilateral subclavian arteries. Main pulmonary artery was plicated. Right innominate artery was bypassed to right subclavian artery, and left carotid artery was bypassed to left subclavian artery with 8 mm biological grafts. Scans showed progressive pulmonary artery aneurysm and patent grafts 12 months postoperatively. Surgery for aneurysm of main pulmonary artery in Behcet's disease should be planned carefully because Behcet's vascular disease can be progressive even after surgery.

Key Words: Behcet's disease; arterial involvement; surgical therapy

ÖZET Behçet Hastalığı'nın arteriyel tutulumunda, cerrahi tedavide anastomotik psödoanevrizma ve greft oklüzyonu insidansı yüksektir. Elli dokuz yaşında erkek hasta kol ağrısı ve nefes darlığı şikayeti ile başvurdu. Özgeçmişinde Behçet Hastalığı mevcuttu. Manyetik rezonans görüntüleme ve bilgisayarlı tomografi ile ana pulmoner arter, sağ innominate arter ve sol subklavian arter proksimalinde anevrizma, bilateral subklavian arterlerde oklüzyon tespit edildi. Ana pulmoner artere plikasyon uygulandı. Sağ innominate arter, sağ subklavian arter ve sol karotis arter de sol subklavian artere 8 mm biyolojik greft ile bypass edildi. Postoperatif 12. ay takibindeki görüntülemede pulmoner arter anevrizmasında ilerleme görüldü ve greftler açık olarak izlendi. Vasküler tutulum gös- teren Behçet hastalarında ana pulmoner arter anevrizma cerrahisi dikkatlice düşünülmelidir, çünkü operasyon sonrasında da tutulum progresyon gösterebilir.

Anahtar Kelimeler: Behçet hastalığı; arteriyel tutulum; cerrahi tedavi

Damar Cer Derg 2014;23(1):47-9

Behcet's syndrome is a multisystemic vasculitis characterized by mucocutaneous, ocular, arthritic, vascular, and central nervous system manifestations. The prevalence is 80 to 370 cases per 100,000 population in Turkey.¹ The male to female ratio is 7:1 in symptomatic forms.² It involves all size and type of vessels including, both arterial and venous system. Venous disease is more common than arterial involvement, and prevalence may account for 14-39% and 3-5% respectively in patients with Behcet's disease respectively.¹⁻³ Thrombosis and/or aneurysms are observed; being predominantly false aneurysms.⁴ Surgical treatment is controversial due to frequent occurrence of graft occlusion and anastomotic pseudoaneurysms.

doi: 10.9739/uvcd.2012-32206

Copyright © 2014 by
Ulusal Vasküler Cerrahi Derneği

CASE REPORT

A 59-years-old male patient had suffered from right arm pain and shortness of breath for 3 years. Medical history revealed Behcet's disease for 14 years. His vital signs were stable on admission. Pulses of both upper extremities were not palpable. There was no other system involvement. Magnetic resonance (MR) angiography of the extremities and computerized tomography of thorax showed that main pulmonary artery was 50 mm; right and left pulmonary arteries were 31 mm and 29 mm, respectively in diameter; right innominate artery aneurysm was 26 mm; left subclavian artery was 20 mm. Right subclavian artery was occluded starting from 1 cm distal to the bifurcation of innominate artery as in these scans (Figures 1A and 1B).

The patient was operated under general anesthesia with median sternotomy to reach the main pulmonary artery, right and left subclavian arteries. Main pulmonary artery was plicated primarily. Anastomoses of left carotico-subclavian and right innominate arteries to the axillary artery were performed using 8 mm biological grafts. Aneurysmatic segment of left subclavian artery was tied up. One mediastinal drainage tube was placed after hemostasis. Sternum was closed with steel wires, as usual.

Postoperative course was uneventful. The patient was discharged on postoperative fourth day. MR angiographies of both extremities and computerized tomography of thorax were obtained 12-months postoperatively. Scans showed that all grafts were patent and progressive native main pulmonary artery aneurysm reached 52 mm in diameter (Figures 2A and 2B).

DISCUSSION

Behcet's Disease is a multisystemic chronic autoimmune inflammatory disease characterized by recurrent oral and genital aphthous ulcers and ocular lesions. Arterial involvement in Behcet's disease is rare, thrombosis and/or aneurysms are observed, being mainly false aneurysms.⁴ These "arterial aphtae" are localized on pulmonary arteries, aorta, renal and peripheral arteries. Vascular surgery is obligatory, but graft thrombosis and relapse of

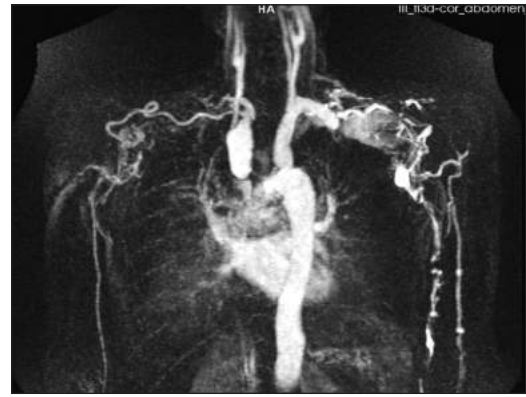

FIGURE 1A: Magnetic resonance imaging: Aneurysm of right innominate artery and occlusion of left subclavian artery.

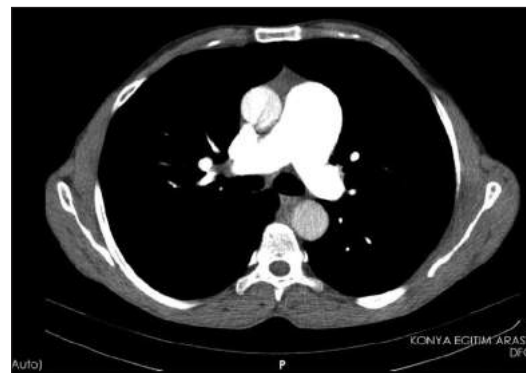


FIGURE 1B: Computerized tomography of thorax: Aneurysm of the main pulmonary artery.

aneurysm at the site of bypass are frequent. The pulmonary aneurysms have a severeredreadful prognosis.⁵ Previous papers reported that graft occlusion or anastomotic pseudoaneurysm tend to occur earlier compared to other diseases.^{3,6} These findings cause difficulties in selecting the surgical procedure and graft material in patients with Behcet's disease. Based on this information, we avoided use of a graft for treatment of pulmonary artery aneurysm. While performing pulmonary artery aneurysm plication, we preferred off-pump clamp and sew technique. The main reason for choosing this technique was to maintain minimal invasion especially to major vascular structures. Although there is not enough evidence to avoid cardiopulmonary bypass, high complication rates of complications and catastrophic risks motivated us to chose off-pump technique. Endovascular stent grafting for recurrent aneurysms is noteworthy for Behcet's disease.⁷ Aneurysms of the distal vessels in Behcet's disease are very infrequent and each case should be evaluated

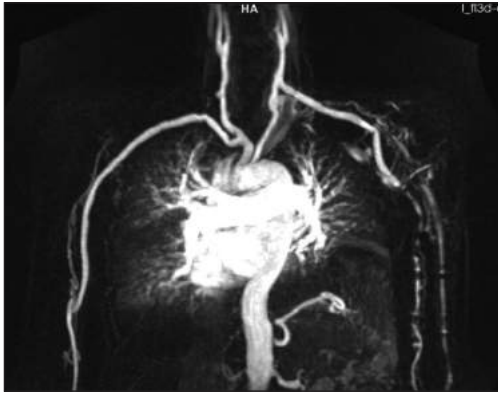


FIGURE 2A: Magnetic resonance imaging: Biological graft of left carotico-subclavian bypass and right innominate artery to axillary artery bypass are patent.

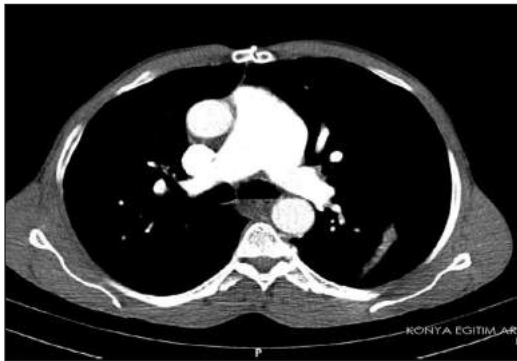

FIGURE 2B: Computerized tomography: Relapsed main pulmonary artery aneurysm.

on an individual basis. Endovascular treatment can be a good alternative therapeutic technique.⁸

This particular case herein fulfilled the diagnostic criteria of Behcet's disease and the aneurysm of the pulmonary artery has been included in the characteristics of the presentation of vascular Behcet's disease. Therefore, we selected pulmonary ar-

tery plication and biological grafts for peripheral bypasses. The scans in the follow-up showed patent grafts and no pseudoaneurysms at the site of the anastomosis. On the other side, pulmonary arterial aneurysm relapsed at postoperative 12 months. Despite the increase in the diameter, we decided to follow up the patient, because he did not have hemodynamic problems and there was no accompanying hemoptysis. In addition, pulmonary artery aneurysm was seen only in the main pulmonary artery. Seyahi et al. reported pulmonary arterial involvement as a poor prognostic factor.⁵ Additionally, Hamuryudan et al. and Tuzun et al. reported series with pulmonary artery aneurysms and concluded that prognosis was poor with high mortality rates in surgically treated patients, especially when accompanying hemoptysis was seen.^{9,10} Saba et al. reported 25% survival rate in 8 patients with a pulmonary artery aneurysm. In this paper, the authors included 23 patients with arterial aneurysms accompanying Behcet's Disease.¹¹ On the other hand, some papers claim that proper immunosuppressant therapy may regress pulmonary artery aneurysm, but these papers have smaller patient numbers.^{13,14}

Surgery for aneurysm of main pulmonary artery in Behcet's disease should be evaluated carefully because Behcet's vascular disease can progressive even after surgery.

Conflict of Interest

Authors declared no conflict of interest or financial support.

REFERENCES

1. Saadoun D, Wechsler B. Behcet's disease. *Orphanet J Rare Dis* 2012;7:20.
2. Yazici H, Fresko I, Tunc R, et al. Behcet's syndrome: pathogenesis, clinical manifestations and treatment in *Vasculitis* by Gene V. In: Ball, S. Louis Bridges ed. 1st ed. Oxford University Press, USA; 2002. p.406-32.
3. Saadoun D, Asli B, Wechsler B, Houman H, Geri G, Desseaux K, et al. Long-term outcome of arterial lesions in Behcet disease: a series of 101 patients. *Medicine (Baltimore)* 2012;91 (1):18-24.
4. Hamuryudan V, Er T, Seyahi E, Akman C, Tüzün H, Fresko I, et al. Pulmonary artery aneurysms in Behcet syndrome. *Am J Med* 2004;117(11):867-70.
5. Seyahi E, Melikoglu M, Akman C, Hamuryudan V, Ozer H, Hatemi G, et al. Pulmonary artery involvement and associated lung disease in Behcet disease: a series of 47 patients. *Medicine (Baltimore)* 2012;91(1):35-48.
6. Hosaka A, Miyata T, Shigematsu H, Shigematsu K, Okamoto H, Ishii S, Hosaka A, Miyata T, Shigematsu H, et al. Long-term outcome after surgical treatment of arterial lesions in Behcet's disease. *J Vasc Surg* 2005;42(1):116-21.
7. Watanabe H, Oda H, Yoshida T, Yamaura M, Takahashi K, Miida T, et al. Endovascular stent-grafting for recurrent aneurysm in Behcet's disease. *Int Heart J* 2005;46(4):745-9.
8. Rico JV, Pedrajas FG, González IC, Segura Iglesias RJ. Urgent endovascular treatment of a ruptured tibio-peroneal pseudoaneurysm in Behet's disease. *Ann Vasc Surg* 2011;25(3): 385.e11-4.
9. Hamuryudan V, Yurdakul S, Moral F, Numan F, Tüzün H, Tüzün N, et al. Pulmonary arterial aneurysms in Behcet's syndrome: a report of 24 cases. *Br J Rheumatol* 1994;33(1):48-51.
10. Tüzün H, Hamuryudan V, Yıldırım S, Beşirli K, Yörük Y, Yurdakul S, et al. Surgical therapy of pulmonary arterial aneurysms in Behcet's syndrome. *Ann Thorac Surg* 1996; 61(2):733-5
11. Saba D, Sarıcaoglu H, Bayram AS, Erdoğan C, Dilek K, Gebitekin C, et al. Arterial lesions in Behcet's disease. *Vasa* 2003;32(2):75-81.
12. Agha A, Bella AM, Assiri AH, Al-Hakami M. Can Behcet's Disease Related Pulmonary Arterial Aneurysms be Completely Resolved? *Open Rheumatol J* 2011;5:88-90.
13. Tunaci M, Ozkorkmaz B, Tunaci A, Gül A, Engin G, Acunaş B. CT findings of pulmonary artery aneurysms during treatment for Behcet's disease. *AJR Am J Roentgenol* 1999;172(3): 729-33.