

# Surgical Treatment of Venous Port Relocalized in the Pulmonary Artery Secondary to Pinch-Off Syndrome Following Implantation: Case Report

## Pinch-Off Sendromuna İkincil Pulmoner Artere Yerleşmiş Venöz Portun Cerrahi Tedavisi

Volkan YURTMAN,<sup>a</sup>  
Sabahattin DALGA,<sup>b</sup>  
Ümid ELÇİ,<sup>c</sup>  
Faig ISAYEV<sup>a</sup>

Clinics of

<sup>a</sup>Cardiovascular Surgery

<sup>b</sup>General Surgery,

<sup>c</sup>Anesthesiology,

Erzurum Şifa Hospital, Erzurum

Geliş Tarihi/Received: 29.04.2013

Kabul Tarihi/Accepted: 16.09.2013

Yazışma Adresi/Correspondence:

Volkan YURTMAN  
Erzurum Şifa Hospital,  
Clinic of Cardiovascular Surgery,  
Erzurum,  
TÜRKİYE/TURKEY  
vol yurt@hotmail.com

**ABSTRACT** Pinch-off syndrome develops due to the compression of the venous catheter between the first rib and clavicle, or between subclavius muscle and costoclavicular ligament, and it is a rarely seen complication. Due to chronic trauma caused by compression, catheter rupture and embolism of the catheter to the pulmonary arteries may develop rarely (0.2-1%). Successive postoperative plain chest X-rays may be useful to define the compression findings. In order to reduce the risk for catheter compression, a more lateral puncture of subclavian vein or "cut-down" to the cephalic vein must be considered. Pinch-off can be avoided by using internal jugular vein for catheterization. In this paper, we present a case of catheter pulmonary embolism developed due to the dislocation of the venous port which was implanted for chemotherapy in a patient diagnosed with colon carcinoma.

**Key Words:** Venous catheter embolism; venous port complications; pulmonary embolism

**ÖZET** Venöz kateterin birinci kosta ile klavikula ve subclavius kas ile kostoklaviküler bağ arasında basısına bağlı olarak gelişen pinch-off sendromu, nadir görülen bir komplikasyondur. Basının neden olduğu kronik travma nedeniyle çok nadir olarak kateter kopması ve kateterin pulmoner arterlere embolisi (%0,2-1) gelişebilir. Lokal operasyon sonrası çekilecek düzenli akciğer grafileri bası bulguları olup olmadığını belirlemede yardımcı olacaktır. Kateter basısı riskini azaltmak için subklavian vene ponksiyon daha lateralden yapılabilir veya sefalik vene "cut-down" uygulanabilir. İnternal juguler ven kullanımı ile de pinch-off sendromundan kaçınılabilir. Bu yazıda, kolon kanseri tanısı alan bir hastada kemoterapi amacıyla takılmış venöz portun ayrılması ile oluşan kateter pulmoner embolisi olgusu, literatür eşliğinde sunuldu.

**Anahtar Kelimeler:** Venöz kateter embolisi; venöz port komplikasyonları; pulmoner emboli

**Damar Cer Derg 2014;23(3):180-2**

Venous port implantation was first described by Niederhuber et al. in 1982. The catheters are inserted completely subcutaneously and provide a safe and easy vessel access for repeated drug administrations. This method has several advantages such as insertion under local anesthesia, causing minimal discomfort, low rate of complications and the ability to administer the treatment immediately after the procedure since patients are discharged on the same day. The most common port complications are thrombosis, infection, catheter obstruction or absence of the blood backflow from the catheter.<sup>1</sup> Totally implantable central venous access devices, or ports, are commonly used for those patients who require long-term or ongoing intravenous infusion therapy. We report a rare port complica-

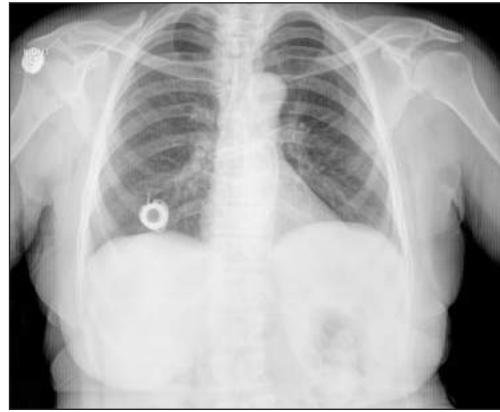doi: 10.9739/uvcd.2013-35941

Copyright © 2014 by  
Ulusal Vasküler Cerrahi Derneği

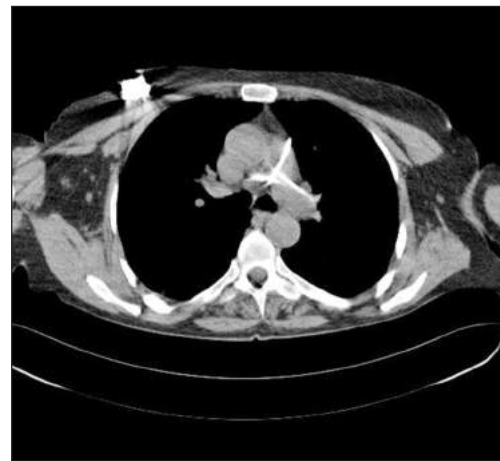tion called pinch-off syndrome, arised due to chronic compression of the central venous catheter between the clavicle and the first rib with consequent mechanic obstruction of the catheter and eventual complete transection and embolization of its distal fragment, and discuss the literature.<sup>2</sup>

## CASE REPORT

A 59-year-old female patient had undergone colon resection due to the colon tumor-related ileus in our hospital 6 months ago. A port was inserted into the right subclavian vein and adjuvant chemotherapy was administered. At follow-up, a control chest X-ray was ordered during the chemotherapy sessions since the venous port did not function, and the patient was referred to our clinic, because the tip of the catheter was found in a different location. Venous port catheter at the right side was removed under local anesthesia. The port container was free and there was not a broken catheter piece in the catheter attachment site. Later, on plain chest X-ray, the tip of the newly inserted catheter was seen to be folded in a ribbon shape beginning from the right ventricle and it was in both pulmonary arteries (Figure 1). The previous plain chest X-rays were examined to see the time of catheter breakage. A computerized tomography (CT) angiogram was ordered for surgical planning. When the images were examined, the catheter was seen to proceed as a whole in the anterior wall of the right ventricle, main pulmonary artery and right-left pulmonary arteries (Figure 2). Anticoagulant therapy was not introduced since the patient had clinical complaints related to pulmonary embolism, and the life expectancy was high. The relatives of the patient were informed; the consents of the patient were received, and an open pulmonary intervention was planned. In order to commence cardiopulmonary bypass easily, the patient underwent standard sternotomy. Aortic and venous cannulation purse-string sutures were inserted following administration of 5000 u crystallized heparin intravenously. Additional 4:0 prolene purse-string sutures were placed to the pulmonary artery at the vertical plane. Pulmonary arteriotomy was performed inside the purse-string, and the catheter was completely removed through



**FIGURE 1:** The venous catheter is seen in the left pulmonary artery on the control posteroanterior chest X-ray of the patient.

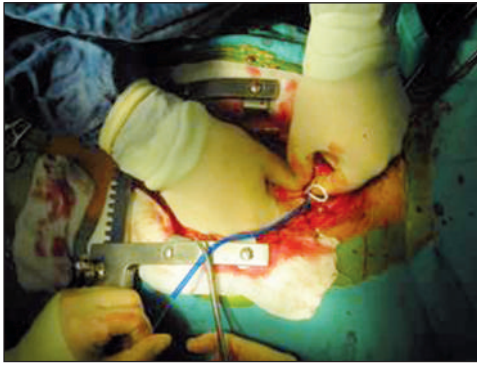


**FIGURE 2:** The appearance of the venous port catheter in the pulmonary artery on thorax computerized tomography.

the purse-string with the help of a hook (Figure 3). A hemodynamic impairment requiring an access to the cardiopulmonary bypass did not occur. When main and access ports of the catheter were examined, it was thought to be dislocated from the port access and moved as a result of the pinch-off syndrome developed due to pinching of the catheter between the first rib and clavicle and between subclavius muscle and costoclavicular ligament.

## DISCUSSION

Venous ports are preferred for the patients requiring intensive treatment implementations such as long term intravenous or aggressive combination chemotherapies, in autologous bone marrow transplantation, or those in a continuous need for par-



**FIGURE 3:** The catheter was removed through a hook following pulmonary arteriotomy.

enteral nutrition.<sup>3</sup> In the majority of the studies, venous port implantations are seen to be safe with low complication rates. In a study retrospectively investigated 1,500 patients who underwent venous port implantation, no complications were seen in 87% of the patients, while infection was reported in 4.8%, thrombosis in 3.2%, catheter malposition in 2.4%, port obstruction in 0.6%, postoperative bleeding in 0.6%, port-related skin necrosis in 0.6%, pneumothorax in 0.27% and catheter rupture in 0.2% and disconnection of the catheter in 0.2%.<sup>1</sup> In another study on 114 patients who underwent venous port implantation, pulmonary embolism due to the rupture of the port was reported in 11 (1%) patients.<sup>4</sup> Port piece was seen in the pulmonary artery 203 days after fixing. Seven of the patients have had no clinical symptoms while pulmonary embolism-induced symptoms occurred in four patients. Nine of these cases were due to pinch-off syndrome, and two were due to disconnection of the catheter. Port piece was excised in all the patients through a snare catheter by accessing it from the right femoral vein and no complications were seen.<sup>4</sup> The most common cause of the catheter rupture is “pinch-off” syndrome. This develops as due to pinching of the catheter between

the first rib and clavicle or subclavius muscle and costoclavicular ligament. Hinke et al. developed a radiographic scale for evaluation of pinch-off syndrome. In this scale, 0= no sign of pinching, 1= direction changes, but there is no pressure, 2= exposure to luminal pressure, 3= completely ruptured.<sup>5</sup> Our patient was compatible with Grade 2. In the 8-year follow-up of 115 oncological patients who underwent venous port implantation, Samancı et al. examined the complications and cost of venous port implantation on 115 patients.<sup>6</sup> Rupture and embolization of the catheter were seen in 5 patients and the catheters were removed using interventional methods. In most of the studies, the port is recommended to be removed in case of the pinch-off syndrome. In our patient, the dislocated catheter was decided to be removed surgically. Because there were not liver, lung or brain metastases due to colon tumor, there was a long life expectancy, the catheter was recognized immediately after the catheter embolization, and the patient presented with the symptoms of pulmonary embolism. When the venous catheter is implanted, subclavian vein puncture, which is carried out to route the catheter should be performed more laterally or it must be inserted directly to the cephalic vein with a cut-down, or an internal jugular vein route should be preferred. All of these measures will reduce the risk for pinch-off syndrome. Venous ports to be used for a long period of time should be periodically controlled with certain intervals through a chest X-ray. The decision to remove the catheter should be made considering the clinic picture and survival expectancy of the patient.<sup>7</sup>

### **Conflict of Interest**

*Authors declared no conflict of interest or financial support.*

## REFERENCES

1. Kock HJ, Pietsch M, Krause U, Wilke H, Eigler FW. Implantable vascular access systems: experience in 1500 patients with totally implanted central venous port systems. *World J Surg* 1998;22(1):12-6.
2. Mirza B, Vanek VW, Kupensky DT. Pinch-off syndrome: case report and collective review of the literature. *Am Surg* 2004;70(7):635-44.
3. Lorch H, Zwaan M, Kagel C, Weiss HD. Central venous access ports placed by interventional radiologists: experience with 125 consecutive patients. *Cardiovasc Intervent Radiol* 2001;24(3):180-4.
4. Surov A, Jordan K, Buerke M, Persing M, Wollschlaeger B, Behrmann C. Atypical pulmonary embolism of port catheter fragments in oncology patients. *Support Care Cancer* 2006;14(5):479-83.
5. Hinke DH, Zandt-Stastny DA, Goodman LR, Quebbeman EJ, Krzywda EA, Andris DA. Pinch-off syndrome: a complication of implantable subclavian venous access devices. *Radiology* 1990;177(2):353-6.
6. Samancı T, Mandel NM, Bozkurt AK, Kutlu F, Uras C. 115 kanser hastasında port komplikasyonlarının değerlendirilmesi. *Cerrahpaşa Tıp Derg* 2004;35:71-7.
7. Staniscia G, Perenze B, De Nicola E, Poti O. [Pinch-off syndrome]. *Ann Ital Chir* 2008;79(6): 463-5.