

Bilateral Extracranial Internal Carotid Artery Aneurysm: Original Image

Bilateral Ekstrakraniyal İnternal Karotis Arter Anevrizması

Aydemir KOÇARSLAN,^a
Mehmet Salih AYDIN,^a
Mert ÜRKÜP,^a
Abdüssemet HAZAR,^a
Mustafa GÖZ^a

^aDepartment of Cardiovascular Surgery,
Harran University Faculty of Medicine,
Şanlıurfa

Geliş Tarihi/Received: 31.01.2014
Kabul Tarihi/Accepted: 21.04.2014

This article was presented as a poster at
14. Congress of Asian Society for
Vascular Surgery, 27-29 October 2013,
İstanbul, Turkey.

Yazışma Adresil/Correspondence:
Aydemir KOÇARSLAN
Harran University Faculty of Medicine,
Department of Cardiovascular Surgery,
Şanlıurfa,
TÜRKİYE/TURKEY
sezay98@gmail.com

Key Words: Carotid artery diseases;
aneurysm

Anahtar Kelimeler: Karotis arter
hastalıkları; anevrizma

Damar Cer Derg 2016;25(2):97-8

doi: 10.9739/uvdc.2014-39036

Copyright © 2016 by
Ulusal Vasküler Cerrahi Derneği

Damar Cer Derg 2016;25(2)

Extracranial internal carotid artery aneurysms are rare and frequently unilateral vascular pathologies that commonly might cause neurologic manifestations.¹

A 63-year-old woman was admitted to our clinic with the complaint of dizziness. Doppler ultrasound and computerized tomography angiography scan demonstrated bilateral fusiform internal carotid artery aneurysms (Figure 1). Left internal carotid artery's diameter was 21 mm and right internal carotid artery's diameter was 11 mm. The patient refused endovascular stent grafting, therefore medical treatment was given including antiaggregants and antihypertensives.

Carotid artery aneurysms occur usually unilaterally at the bifurcation of common carotid artery,² but in our case, aneurysms were bilateral. Thromboembolic and neurological complications due to nerve compression are common. Another catastrophic adverse event may be rupture with massive hemorrhage, but only dizziness was found in our case.³ Antiplatelet and anticoagulant medications are considered as the primary approach for asymptomatic aneurysmal lesions, and aneurysm surgery still remains the most suitable option to prevent the most probable, severe and life-threatening complications, in particular embolisms and rupture.⁴

Conflict of Interest

Authors declared no conflict of interest or financial support.

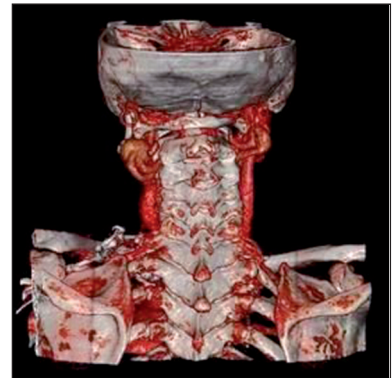


FIGURE 1: Bilateral fusiform aneurysms of extracranial internal carotid artery. Left internal carotid artery's diameter is 21 mm, right internal carotid artery's diameter is 11 mm.

REFERENCES

1. Odabaşı D, Başel H, Kıymaz A, Ekim H. Extracranial Internal Carotid Artery Aneurysm; Case Report. Van Medical Journal 2011;18(3): 165-8.
2. Reslan OM, Ebaugh JL, Raffetto JD. Bilateral asymptomatic extracranial carotid artery aneurysms. Ann Vasc Surg 2010;24(5): 691.e11-6.
3. Rosset E1, Albertini JN, Magnan PE, Ede B, Thomassin JM, Branchereau A. Surgical treatment of extracranial internal carotid artery aneurysms. J Vasc Surg 2000;31(4):713-23.
4. El Sabrout and Cooley. Extracranial carotid artery aneurysms: Texas Heart Institute experience. J Vasc Surg 2000;31(4):207-12.