

Treatment of Isolated Common Iliac Artery Aneurysm with Iliac Branched Endograft: Case Report

İliyak Dallı Endogreft ile İzole Ana İliyak Arter Anevrizma Tedavisi

Murat CANYİĞİT,^a
Mete HİDİROĞLU,^b
Mehmet Akif TEBER,^a
Aslıhan KÜÇÜKER,^b
Gökçe AKGÜNDÜZ,^a
Fethi SAĞLAM^b

Departments of
^aRadiology,
^bCardiovascular Surgery,
Ankara Atatürk Training and
Research Hospital, Ankara

Geliş Tarihi/Received: 09.03.2013
Kabul Tarihi/Accepted: 10.06.2013

Yazışma Adresi/Correspondence:
Aslıhan KÜÇÜKER
Ankara Atatürk Training and
Research Hospital,
Department of Cardiovascular Surgery,
Ankara,
TÜRKİYE/TURKEY
asliastan@yahoo.com

ABSTRACT Aneurysms of the iliac arteries are frequently associated with abdominal aortic aneurysms and isolated common iliac artery aneurysms are very rare. The risk of rupture and mortality in patients with untreated isolated iliac artery aneurysm is very high. In recent years, endovascular treatment has become a successful alternative to open surgery. One of the options for endovascular treatment consists of excluding the aneurysm from the vascular system via tubular stent-graft after occlusion of the internal iliac artery. Ischemic complications may be seen frequently after this procedure. Iliac branched endograft, also called as iliac bifurcation device, has been introduced to eliminate these complications. Herein, we present a 52-year-old male case with isolated fusiform right common iliac artery aneurysm extending to the iliac bifurcation which was successfully treated with iliac branched endograft for the first time in Turkey.

Key Words: Iliac aneurysm; iliac branched endograft; endovascular treatment

ÖZET İliyak arterlerin anevrizmaları sıklıkla abdominal aort anevrizmaları ile ilişkide olmalarına rağmen, izole ana iliyak arter anevrizmaları oldukça nadirdir. Tedavi edilmeyen izole iliyak arter anevrizmasının rüptür ve mortalite riski oldukça yüksektir. Son zamanlarda endovasküler tedavi, açık cerrahiye başarılı bir alternatif tedavi olmuştur. Endovasküler tedavi için seçeneklerden biri, internal iliyak arterin tıkanması sonrası tübüler stent-greft ile anevrizmanın vasküler sistemden uzaklaştırılmasıdır. Bu işlem sonrası iskemik komplikasyonlar yüksek oranda görülebilmektedir. İliyak bifurkasyon aleti olarak da adlandırılan iliyak dallı endogreft, bu komplikasyonları ortadan kaldırmak için üretilmiştir. Biz bu yazıda, 52 yaşındaki erkek olguda Türkiye’de ilk kez bir iliyak dallı endogreft ile iliyak bifurkasyona uzanan izole fuziform sağ ana iliyak arter anevrizmasının başarılı tedavisini sunduk.

Anahtar Kelimeler: İliyak anevrizma; iliyak dallı endogreft; endovasküler tedavi

Damar Cer Derg 2014;23(2):120-3

Isolated common iliac artery aneurysms are rarely seen in older people with a prevalence varying between 0.008% and 0.03%.¹ In recent years, branched iliac endografts have been produced to preserve internal iliac artery flow in treatment of common iliac artery aneurysms and especially for the ones associated with abdominal aortic aneurysms.² The aim of this report is to share our experience in endovascular treatment of an isolated fusiform common iliac artery aneurysm extending to the iliac bifurcation by using an branched iliac endograft for the first time in Turkey.

doi: 10.9739/uvcd.2013-35077

Copyright © 2013 by
Ulusal Vasküler Cerrahi Derneği

CASE REPORT

Fusiform aneurysm of the right common iliac artery was incidentally detected in a 52-year-old man with ulcerative colitis on abdominal magnetic resonance imaging. His physical examination and the laboratory tests were normal. He had a history of smoking for 30 years. Further evaluation was performed with abdominal computed tomography (CT) angiography revealing fusiform aneurysm of the right common iliac artery extending to the iliac bifurcation with a diameter of 32 mm (Figure 1). The patient was scheduled for an elective endovascular treatment by using an iliac branched endograft.

Bilateral common femoral arteries were surgically prepared under general anesthesia. Systemic anticoagulation was achieved with an intravenous bolus dose of 5,000 IU heparin. Subsequently, 6 Fr short sheaths were placed into both femoral arteries. Standard 0.035-inch guidewire was advanced inside the 5Fr Bern catheter, passing through the aneurysmatic segment via the right femoral artery and 0.035-inch extra stiff guide wire (Lunderquist; Cook Inc., Bloomington, IN, ABD) was inserted through the catheter after withdrawing the standard guidewire. Over the stiff guidewire, the tip of Zenith® iliac branched endograft (Cook Inc.,

Bloomington, IN, USA) was placed above the aortic bifurcation. Endograft was unsheathed partially until the already loaded catheter and guidewire tip appear. While the guidewire was being advanced into the terminal aorta, a snare (EN snare; Merit Medical Systems Inc., South Jordan, Utah, USA) was inserted via left femoral artery aiming to capture the guidewire. Thus, a safe line was acquired by the preloaded guidewire (through-and-through wire) on both of the femoral arteries. Then, the endograft was unsheathed until the side branch was released. A 12Fr Balkin sheath (Cook Inc., Bloomington, IN, USA) was inserted over the through-and-through wire and directed inside the opened proximal part of the endograft. Unfortunately, we failed due to extreme angulation of the iliac arteries. Therefore, a 7Fr sheath (Cook Inc., Bloomington, IN, USA) was advanced over the through-and-through wire within the 12Fr sheath, and was placed in the proximal part of the endograft. We tried to advance the 12Fr sheath over the 7Fr sheath again, but unfortunately we were not successful. A Bern catheter and a guidewire were preferred within the 7Fr sheath to cannulate the internal iliac artery. A 0.035-inch 260 cm Amplatz stiff wire (Boston Scientific, Global Park, Heredia, Costa Rica) was then placed through the catheter, and the 7Fr sheath and Bern catheter were removed. While 12Fr sheath was next to the proximal endograft, a 10x60 mm self-expandable covered stent (Fluency®; Angiomed GmbH&Co., Karlsruhe, Germany) was inserted over the stiff wire and deployed. Subsequently, the covered stent was reinforced by a 10x40 mm self-expandable bare stent (Resistant; Eucatech AG, Rheinfelden, Germany).

Afterwards, the proximal and distal segments of the endograft were released. A second 16x60 mm tubular stent-graft (Cook Inc., Bloomington, IN, USA) was placed between the terminal aorta and iliac branched endograft. Digital subtraction angiography revealed appropriately positioned stents, unhindered internal iliac artery flow, and no endoleaks (Figure 2).

After one day intensive care unit stay, the patient was taken into cardiovascular surgery ward. The patient was discharged uneventfully on the

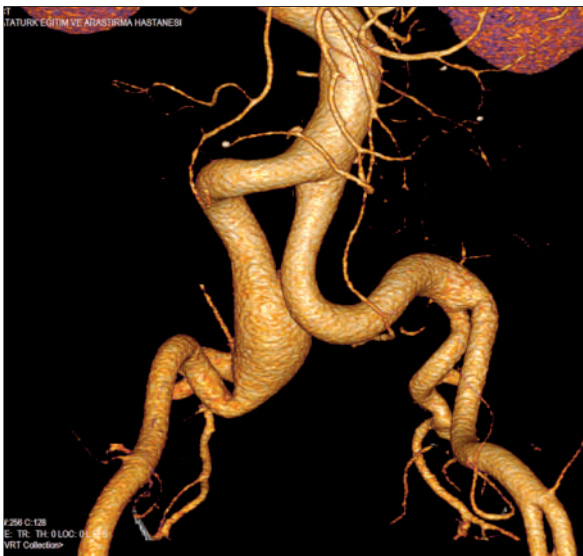

FIGURE 1: 3-D reformatted computerized tomographic angiography image shows isolated fusiform right common iliac artery aneurysm extending to the iliac bifurcation and excessive angulation of the iliac arteries.

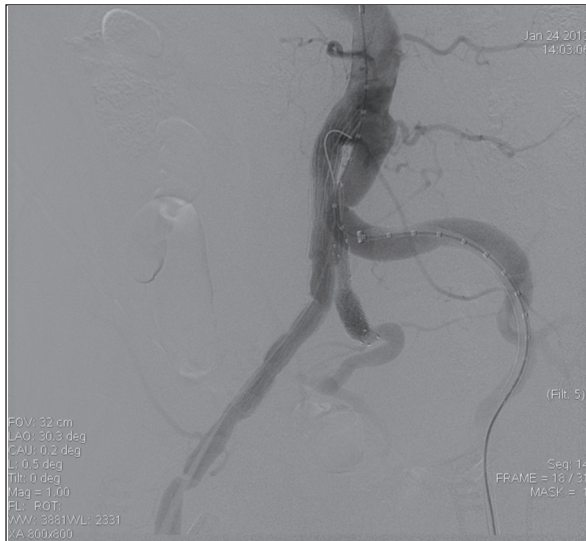


FIGURE 2: Digital subtraction angiography obtained after deployment of the stent-grafts shows appropriate position of the stent-grafts, patent internal iliac artery, and no filling of the aneurysm.

fourth postoperative day. Abdominal CT angiography on 30th postoperative day showed no aneurysm or endoleak and the internal iliac artery was intact (Figure 3).

DISCUSSION

Iliac artery aneurysms are frequently seen in conjunction with abdominal aortic aneurysms and isolated common iliac artery aneurysms are very rare.³ Unilateral iliac artery aneurysms are seen in 43% and bilateral common iliac artery aneurysms are seen in 11% of the patients with abdominal aortic aneurysms.⁴ The management of iliac artery aneurysms differs according to the inclusion of abdominal aorta in the aneurysmatic segment. Elective treatment is indicated in isolated iliac artery aneurysms greater than 3 cm. Since maximum recommended iliac artery diameter is 2 cm for the stent-grafts used in endovascular aortic repair, the indicated diameter for common iliac artery enlargement accompanying abdominal aortic aneurysm is 2 cm.^{5,6} Aneurysms involving only the iliac arteries are to be treated since they may cause devastating complications. The frequency of rupture in patients with untreated isolated iliac artery aneurysm is 67%, while the mortality rate is 90%.⁷

Along with the development of endovascular techniques and materials, endovascular treatment has become a successful alternative to open surgery in treatment of both iliac artery aneurysms accompanying abdominal aortic aneurysms and isolated iliac artery aneurysms.⁸ One of the options for endovascular treatment of common iliac artery aneurysm extending to the iliac bifurcation consists of excluding the aneurysm from the vascular system via tubular stent-graft after occlusion of the internal iliac artery. After this procedure, ischemic complications such as hip or thigh claudication, colitis, gluteal necrosis, sexual dysfunction, and spinal cord injury may be seen after occlusion of the unilateral internal iliac artery at a rate of 16- 50%. The complication rate may increase up to 80% in bilateral internal iliac artery occlusion.^{9,10}

Iliac branched endograft, also called as iliac bifurcation device, has been developed to protect internal iliac artery flow in the treatment of common iliac artery aneurysm extending to bifurcation. The applicability of this endograft necessitates secure segments with normal vessel diameters. Therefore, external iliac artery length and diameter should be at least 20 mm and 8-11 mm, respectively, for pro-

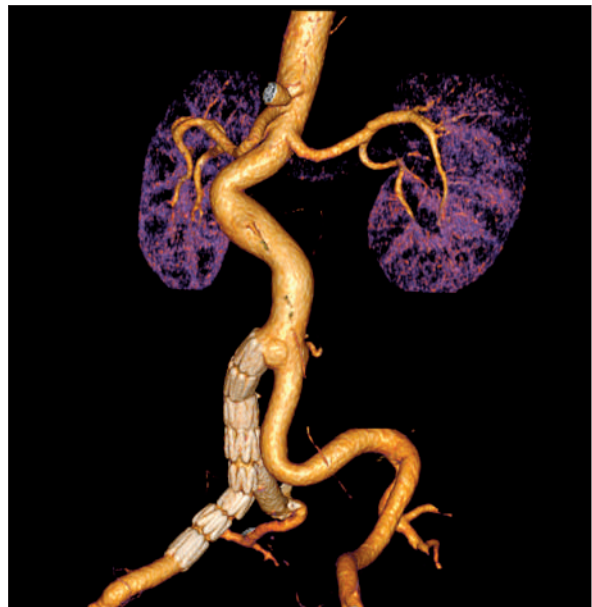

FIGURE 3: 3-D reformatted CT angiography image obtained at the 4th postoperative day shows successful exclusion of right common iliac artery aneurysm with iliac branched endograft by preserving internal iliac artery.

viding a secure segment to be able to insert the endograft. Furthermore, internal iliac artery should also have a secure segment with a normal diameter and a length of minimum 10 mm as well.

Although balloon-expandable Advanta V12® covered stent (Atrium Medical, Hudson, New Hampshire, USA) is much more preferred to be placed in the internal iliac artery, we preferred self-expandable Fluency® covered stent since we could not obtain the former one at the procedure. We did not prefer self-expandable Viabahn® covered stent due to its higher flexibility. In order to avoid a possible break and/or bend in the self-expandable covered stent, we also placed a second bare stent inside it.

During the intervention, 7Fr sheath inside the 12Fr sheath was easily advanced from the proximal segment of the endograft, but 12 Fr sheath could not be advanced due to extreme angulation of the iliac arteries. Paying attention to this difficulty we experienced, we assume that Advanta V12® covered stent

seems to be more appropriate for internal iliac artery stenting compared to the other covered stents since it has the lowest crossing profile (e.g. 7 Fr sheath is enough for 10 mm) and there is no need for a second bare stent inside it. However, despite we were not able to place 12 Fr sheath inside the endograft, we could accomplish to advance Fluency® covered stent easily into internal iliac artery. Consequently, we consider that the Fluency® covered stent is a feasible alternative option in such cases.

In conclusion, iliac branched endograft is an effective and feasible alternative treatment option in order to avoid pelvic ischemic complications in the management of isolated common iliac artery aneurysms extending to iliac bifurcation. Further studies are needed to determine long-term durability of this device in these patients.

Conflict of Interest

Authors declared no conflict of interest or financial support.

REFERENCES

1. Brunkwall J, Hauksson H, Bengtsson H, Bergqvist D, Takolander R, Bergentz SE. Solitary aneurysm of the iliac artery system: an estimate of their frequency of occurrence. *J Vasc Surg* 1989;10(4):381-4.
2. Dias NV, Resch TA, Sonesson B, Ivancev K, Malina M. EVAR of aortoiliac aneurysms with branched stent-grafts. *Eur J Vasc Endovasc Surg* 2008;35(6):677-84.
3. Oztürk MH, Eyüboğlu I, Pulathan Z, Dinç H. Spontaneous thrombosis of a saccular iliac artery aneurysm induced by overlapping self-expandable bare metallic stents. *Diagn Interv Radiol* 2010;16(4):308-11.
4. Karthikesalingam A, Hinchliffe RJ, Holt PJ, Boyle JR, Loftus IM, Thompson MM. Endovascular aneurysm repair with preservation of the internal iliac artery using the iliac branch graft device. *Eur J Vasc Endovasc Surg* 2010;39(3):285-94.
5. Kasirajan V, Hertzner NR, Beven EG, O'Hara PJ, Krajewski LP, Sullivan TM. Management of isolated common iliac artery aneurysms. *Cardiovasc Surg* 1998;6(2):171-7.
6. Lee WA. Branched endograft for aortoiliac artery aneurysms. *Vascular* 2009;17 Suppl 3: S111-8.
7. Brin B, Busuttil R. Isolated hypogastric artery aneurysms. *Arch Surg* 1982;117(10):1329-33.
8. Hechelhammer L, Rancic Z, Pfiffner R, Mayer D, Meier T, Lachat M, et al. Midterm outcome of endovascular repair of ruptured isolated iliac artery aneurysms. *J Vasc Surg* 2010;52(5): 1159-63.
9. Oderich GS, Greenberg RK. Endovascular iliac branch devices for iliac aneurysms. *Perspect Vasc Surg Endovasc Ther* 2011;23(3): 166-72.
10. Rayt HS, Bown MJ, Lambert KV, Fishwick NG, McCarthy MJ, London NJ, et al. Buttock claudication and erectile dysfunction after internal iliac artery embolization in patients prior to endovascular aortic aneurysm repair. *Cardiovasc Intervent Radiol* 2008;31(4):728-34.