

Marginal Vein is Not a Simple Varicose Vein: It is a Silent Killer!: Invited Article

Marjinal Ven Basit Bir Variköz Ven Değildir: Sessiz Bir Katildir!

Byung-Boong LEE^a

^aProfessor of Surgery and Director,
Center for the Lymphedema and
Vascular Malformations,
George Washington University,
Washington DC, USA
Adjunct Professor of Surgery,
Uniformed Services University of
the Health Sciences, Bethesda, MD, USA
Clinical Professor of Surgery,
Johns Hopkins University
School of Medicine, USA
Emeritus Professor of Surgery,
Georgetown University,
Washington DC, USA

Geliş Tarihi/Received: 02.01.2013
Kabul Tarihi/Accepted: 03.01.2013

Yazışma Adresi/Correspondence:
Byung-Boong LEE
Professor of Surgery and Director,
Center for the Lymphedema and
Vascular Malformations,
George Washington University,
Washington DC, USA
Adjunct Professor of Surgery,
Uniformed Services University of
the Health Sciences, Bethesda, MD, USA
Clinical Professor of Surgery,
Johns Hopkins University
School of Medicine, USA
Emeritus Professor of Surgery,
Georgetown University,
Washington DC, USA

doi: 10.9739/uvcd.2013-33561

Copyright © 2013 by
Ulusal Vasküler Cerrahi Derneği

ABSTRACT Marginal vein (MV) is not an ordinary varicose vein; it is an embryonic vein remnant classified as a truncular venous malformation (VM). MV is the result of defective development along the later stage of embryogenesis while the vein trunk is formed. MV exists most often with Klippel Trenaunay Syndrome (KTS), representing as its major VM component; VM is a part of combined form of congenital vascular malformation (CVM) involved with KTS together with the lymphatic malformation. MV accompanies a high risk of venous thromboembolism due to defective vessel structure with a lack of smooth muscle cell to form the media in addition to a valvulosis condition, often resulting in fatal pulmonary embolism. Early ablation of the MV is indicated whenever feasible as far as the deep vein system is normal, especially when the MV causes a vascular bone syndrome. Otherwise, prophylactic anticoagulation is strongly recommended.

Key Words: Varicose veins; Klippel-Trenaunay-Weber Syndrome

ÖZET Marjinal ven (MV) basit bir variköz ven değildir. Bu bir embriyolojik ven kalıntısıdır ve bir trunkular malformasyon olarak sınıflandırılır. MV venöz trunk oluşurken embriyogenezin geç dönemindeki defektif gelişime bağlı ortaya çıkar. MV en sık Klippel-Trenaunay Sendromu (KTS) ile birlikte ve onun majör bir komponentidir. VM Konjenital Vasküler Malformasyonun (CVM) kombine bir formudur. KTS'de lenfatik malformasyon ile birlikte olabilir. MV, defektif damar yapısı nedeniyle yüksek bir venöz tromboembolizm riskine sahiptir. Media tabakasında düz kas hücreleri olmadığı gibi, kapakçıklardan da yoksundur. Sıklıkla ölümcül pulmoner embolilere neden olur. Uygun olduğunda, derin venöz sistem normal olduğu sürece MV'nin erken ablasyonu gereklidir. Özellikle de MV'nin bir vasküler kemik sendromuna neden olduğu durumlarda. Bunun dışında profilaktik antikoagülasyon güçlü bir şekilde önerilir.

Anahtar Kelimeler: Variköz venler; Klippel-Trenaunay-Weber Sendromu

Damar Cer Derg 2013;22(1):4-14

Marginal vein (MV)¹⁻⁵ is relatively common among various congenital vascular malformations (CVMs) affecting lower extremity;⁶⁻¹⁰ it often mimics the ordinary varicose veins originated from saphenous/superficial vein. However the MV is NOT a varicose vein. It is an embryonic vein remnant which failed to involute as a birth defect.

Although MV often runs along the lateral aspect of the lower extremity, which is an odd/unusual location for common varicose veins, it usually locates very superficially beneath the skin with a minimum soft tissue coverage so that most of the MV looks very innocuous, confusing the phlebologists with the varicose vein (Figure 1).

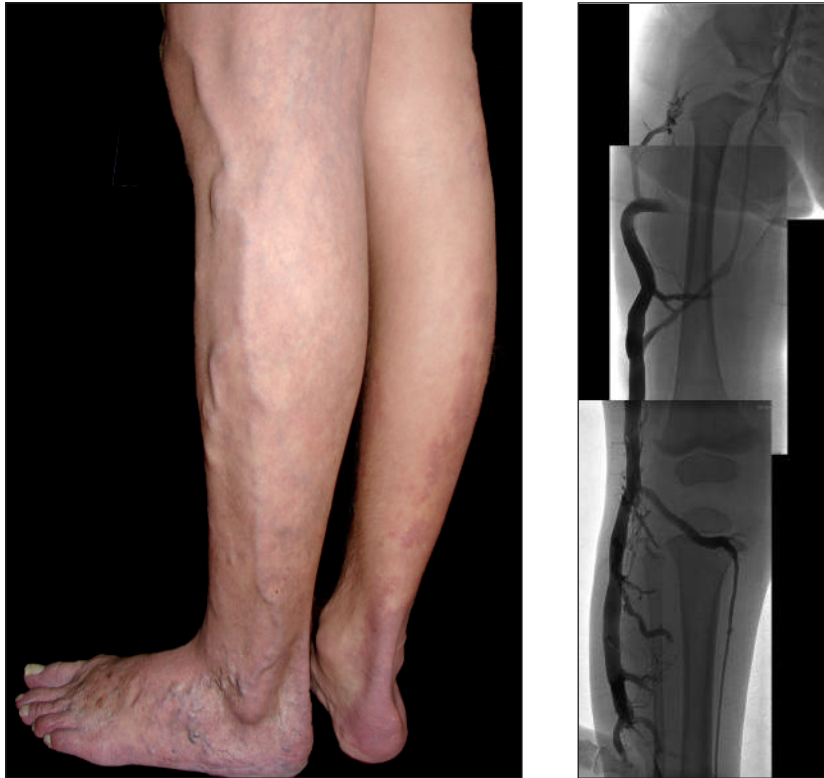

FIGURE 1: **1A** depicts a clinical condition of the marginal/lateral embryonic vein along the lateral aspect of the left lower extremity. This unique vein structure is a persistent fetal remnant vessel following the failure of normal involution/regression.

1B presents an angiographic finding of this marginal vein, which remains the only major venous drainage route for this patient with a lack of normal development of deep venous system. Therefore, surgical excision to control the venous hypertension is contraindicated.

(From: Lee BB. Venous embryology: the key to understanding anomalous venous conditions. *Phlebology*. 2012;19(4):170-81).

Depending upon the stage of defective development along the last/truncular stage of embryogenesis while forming the vein trunk, the extent and severity of the MV are different so that all the MVs in different conditions as well as different locations are named together as 'lateral embryonic vein' including the 'sciatic vein'.^{2,11,12}

Regardless of the location and severity, all these laterally located embryonic veins have same defective/deficient media of the vein wall with lack of smooth muscle layers (cf. varicose vein).

The MV is the most common form of venous malformation (VM) involved to Klippel-Trenaunay Syndrome (KTS)¹³⁻¹⁷ as one of its multiple vascular malformation components.

KTS is a well known name-based eponym representing a clinical condition of various congenital anomalies affecting not only the vascular system but also the soft tissue as well as the skeletal system.

The MV/lateral embryonic vein as a truncular VM¹⁻⁵ is potentially most dangerous VM involved with KTS, and together with extratruncular VM, it represents the VM group of CVM components of KTS.

In addition to this VM group,¹⁸⁻²¹ KTS has the lymphatic malformation (LM) group,²²⁻²⁴ as another clinically significant CVM components, to affect the majority of clinical condition of KTS directly and indirectly besides capillary malformation (CM).^{25,26} These two, VM and LM, combined form of CVMs are classified as 'hemolymphatic malformation' (HLM) by modified Hamburg Classification (Table 1).²⁷⁻³⁰

Nevertheless, the MV has been considered a relatively benign condition causing only chronic venous insufficiency (CVI) by its natural condition of avalvulosis- lack of venous valve- as a part of defective development of the venous wall.¹⁻⁵ However la-

TABLE 1A: Hamburg Classification* of Congenital Vascular Malformations (CVMs) - Types.

Predominantly arterial defects
Predominantly venous defects
Predominantly AV (arteriovenous) shunting defects
Predominantly lymphatic defects
Combined vascular defects

* Based on the consensus on CVM through the international workshop in Hamburg, Germany, 1988, and subsequently modified.

* Capillary malformation was not included.

TABLE 1B: Hamburg Classification of CVMs*: Forms - Embryological subtypes.

1. Extratruncular forms
■ Infiltrating, diffuse
■ Limited, localized
2. Truncular forms
■ Aplasia or obstruction Hypoplasia; Aplasia; Hyperplasia Stenosis; Membrane; Congenital spur
■ Dilatation Localized (aneurysm) Diffuse (ectasia)

* Represents developmental arrest at the different stages of embryonic life: Earlier stage – Extratruncular form; Later stage – Truncular form.

* Both forms may exist together; may be combined with other various malformations (e.g. capillary, arterial, AV shunting, venous, hemolympathic and/or lymphatic); and/or may exist with hemangioma.

tely, MV was found to be a much more serious condition to cause the venous thromboembolism (VTE). When this MV is combined with a unique condition of coagulopathy, which is common among the ‘extratruncular’ VM lesions, it becomes a source of often fatal pulmonary embolism (PE).³¹⁻³⁴

Hence, a proper understanding on the MV as one of CVMs is mandated for a safe management as a whole.

DEFINITION AND CLASSIFICATION OF THE CONGENITAL VASCULAR MALFORMATIONS (CVMs)

CVM represents a group of defective vascular structures as the outcome of developmental arrest during various stages of embryogenesis. Depending

upon the embryological stage when the defective development occurs, its clinical behavior is entirely different so that a precise understanding of this embryological background of every CVM lesion is warranted.³⁵⁻³⁹

When the defective development occurs in its ‘early’ stage while the vascular structure is still in primitive condition of reticular network, this embryonic tissue will remain presenting as a cluster of malformed vessels on birth. Therefore, this in-born vascular defect exists already at birth and continues to grow at a rate that is proportional to the growth rate of the body (cf. hemangioma), and classified into the ‘extratruncular’ type to differentiate from ‘truncular’ type which represents other group of defective development originated from the ‘late’ stage.

This CVM group belongs to the ‘vascular anomaly’ together with the vascular tumor group represented by (neonatal or infantile) hemangioma.⁴⁰⁻⁴³ Although both groups represent entire anomalous vascular disorders/structures as a vascular anomaly, regardless if its origin and pathogenesis, the CVMs and vascular tumor/hemangioma are totally different not only for their pathogenesis but also for their clinical behavior.

The (infantile/neonatal) hemangioma originates from the endothelial cells so that it has a distinct growth cycle characterized by a proliferation phase of early rapid growth followed by an involutional phase of slow regression. Unlike CVMs, it usually appears in the early neonatal period among perfectly normal neonates and undergo ‘self-limited’ growth followed by subsequent involution that usually completes before the age of 5-10 years in the majority of cases (Figure 2).

Until past three decades, there had been a significant confusion on the definition on various vascular defects based on mostly name-based eponyms; this old classification failed to provide essential information regarding the etiology, anatomy, and pathophysiology due to lack of sufficient knowledge before modern technology was available for a precise evaluation of these complex vascular conditions.⁴⁴⁻⁴⁷

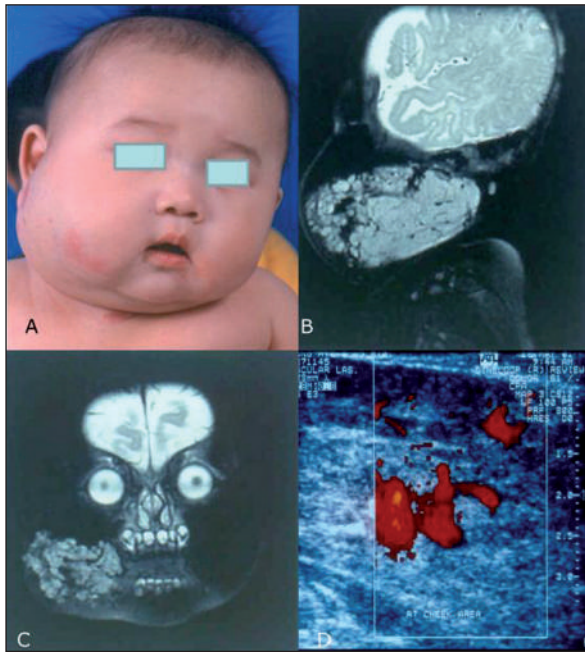


FIGURE 2: **2A** depicts clinical condition of (infantile) hemangioma as a rapidly expanding lesion along the right cheek, first noted a few months after birth, which may be mistaken for a venous malformation.

2B & 2C show typical MRI findings of (infantile) hemangioma, affecting right cheek with prominent vascularity that helps differentiate it from a common VM. **2D** presents Duplex ultrasonographic findings of active/high blood flow through the lesion in contrast to what would be found in a VM lesion.

(From: Lee BB, Laredo J, Lee TS, Huh S, Neville R. Terminology and classification of congenital vascular malformations. *Phlebology*. 2007; 22(6):249-52).

New classification was formulated for the first time through the workshop held in Hamburg, Germany in 1988 to compensate the old name-based eponyms (e.g. KTS).²⁷⁻³⁰ Although these eponyms are still useful to describe certain conditions involved in combined forms of vascular malformations, their roles have been largely replaced by new (Hamburg) classification for the last two decades.

The Hamburg Classification System appropriately classifies CVMs using criteria that take into account the underlying anatomical, histological, pathophysiological, and hemodynamic status of these congenital vascular defects from different embryonic stages. Modern technology and improved diagnostic studies has allowed accurate diagnosis of these lesions, which is critical for accurate classification.

The Hamburg Classification distinguished the CVMs to six clinically and hemodynamically dif-

ferent groups, and named them after the vascular systems involved in the predominant lesion: arterial (AM),^{48,49} venous,⁵⁰⁻⁵³ arterio-venous (AVM),⁵⁴⁻⁵⁷ lymphatic LM,⁵⁸⁻⁶¹ capillary,^{25,26} and combined vascular malformations.⁶²⁻⁶⁴ When LM⁶⁵⁻⁶⁷ is mixed/co-exists with VM or AVM⁶⁸⁻⁷⁰ as a combined form of the CVM, they were named as Hemolymphatic Malformation (HLM) (Table 1A).^{10,18}

Each CVM group is further subdivided into Extratruncular and Truncular Forms in the Hamburg classification, based on the embryological stage when developmental arrest has occurred (Table 1B).²⁷⁻³⁰

The “extratruncular form” of CVM lesions arise when developmental arrest occurs in the ‘earlier stage’ of embryonic life while the vascular system is in the reticular stage. Extratruncular lesions therefore, retain the characteristics of the mesenchymal cells (angioblasts) as embryonic tissue remnants of mesodermal origin. It retains its potential to grow and proliferate when stimulated internally (e.g. menarche, pregnancy, and hormone) or externally (e.g. trauma, surgery).³⁵⁻³⁹

The “truncular form” of CVM lesions arise when developmental arrest occurs during the vascular trunk formation period in the ‘later stage’ of the embryonic development.³⁵⁻³⁹ Truncular lesions have lost the embryonic characteristics of the mesenchymal cells along with the potential to grow and proliferate. Thus, these truncular lesions carry minimal risk of recurrence on contrary to the extratruncular lesion. Truncular lesions however, are associated with more serious hemodynamic consequences related to the type of CVM (e.g. marginal and embryonic veins as truncular VM).

Accordingly, extreme varieties of CVM lesions with a wide range of clinical presentations, unpredictable clinical course, and erratic response to treatment with the potential for high rates of recurrence can be explained based on this embryological background; the clinical behavior of every vascular malformation is dependent on unique embryological characteristics of different stages of embryogenesis at which developmental arrest occurs.⁷¹⁻⁷⁴

This new (Hamburg) classification provided the impetus for the development of a contemporary concept of CVMs based on embryological subclassification into one of two different subtypes, truncular or extratruncular, allowing clinicians to predict the clinical course, response to treatment and likelihood of recurrence. With the Hamburg classification, precise diagnosis of various CVMs became feasible based on modern technology.^{10,27-30}

DEFINITION AND CLASSIFICATION OF THE VENOUS MALFORMATIONS (VMs)

VMs are developmental anomalies (birth defects) limited to the venous system only. They are the result of arrested/defective development of the venous system during the various stages of embryogenesis. VM is one of the most common CVMs, and together with arterial, capillary and lymphatic malformations, they are part of a large group of CVMs (Table 1).⁷⁵⁻⁷⁸

The terms “capillary or cavernous hemangioma” are still used erroneously to describe a VM lesion and should no longer be used in order to avoid confusion with a genuine hemangioma which belongs to a vascular tumor and NOT a vascular malformation.^{10,18}

Numerous classifications of VMs have been proposed before the Hamburg Classification was available as a universal classification system; many were based on the appearance of the anomaly, its anatomy, pathology, or based on the velocity of blood flow in the lesion (e.g. cavernous hemangioma; cavernous angioma; phlebangioma). Many VMs are still named after the clinician who first described the lesion resulting in redundant terminology with more confusion.

EXTRATRUNCULAR VM LESIONS (TABLE 1B)

The defective development of these lesions occurs before the main vascular trunks are formed (pre-truncular embryonic lesions). Therefore, the lesions never involve the main trunk of formed vein itself but remain as an independent lesion from the named/matured vein. These lesions respond to various stimuli and proliferate, carrying a high risk of recurrence following the treatment.

These lesions are further subdivided into diffuse, infiltrating lesions and localized, limited lesions. Diffuse, infiltrating extratruncular VM lesions may cause symptoms due to compression of the surrounding structures (muscles, nerves). They may produce significant hemodynamic impact on the involved venous system that is dependent on lesion size and location including the risk of coagulopathy. Growth is usually slow and proportionate to the person's growth like other extratruncular CVM lesions throughout the rest of the person's life and there is no spontaneous regression like a hemangioma.

TRUNCULAR VM LESIONS (TABLE 1B)

The defective development of these lesions occur long after the primitive reticular stage of vascular development. These lesions are also known as “post-truncular fetal lesions” since the defective development occurs along the late stage while the vascular trunk is formed. Truncular lesions therefore, no longer carry the risk of recurrence after treatment. However, these lesions have varying degrees of hemodynamic consequences due to congenital valvular incompetence, obstruction (atresia, hypoplasia) or dilatation/aneurysm formation with associated risk of VTE especially when the condition is combined with a consumptive coagulopathy, common phenomenon among the extratruncular VM lesions.

The truncular lesions are further subdivided into obstructive⁷⁹⁻⁸² or dilated⁸³⁻⁸⁶ lesion types. All truncular lesions involve often ‘named’ vein trunk (e.g. femoral, popliteal, iliac veins); they present as a deformed vein with various degrees of developmental defect (e.g. agenesis/rudimentary deep vein), ranging from incomplete or immature lesions (aplasia or hypoplasia) to overdeveloped lesions (hyperplasia) directly affecting the main axial veins (cf. extratruncular lesion).

Therefore, these truncular VM lesions clinically manifest as a defective vessel either as an obstruction (e.g. vein web, spur, annulus, or septum)⁸⁷⁻⁹⁰ or dilatation (e.g. popliteal or iliac vein ectasia/aneurysm).⁹¹⁻⁹⁴ Avalvulia/avalvulosis, or absence of valves is another form of hypoplasia that

produces venous reflux which is a hallmark of the MV. Together with atresia of the lumen of venous trunks and venous aneurysms, these are relatively common VM lesions.⁹⁵

Another unique form of truncular VM lesions is a persistent fetal remnant (truncal) vessel as persistent, large, embryonic veins such as the MV or the sciatic vein when a fetal (truncal) vessel fails to undergo normal involution.¹⁻⁵

DEFINITION-MARGINAL VEIN (MV)

The truncal venous development of the lower extremity goes through three stages to form matured veins along the later stage of embryogenesis and the MV/lateral embryonic vein is the result of defective development of vein trunk formation through these three stages as following;^{11,12}

Early venous outflow from the primitive lower limb is established through a lateral/posterior fibular (peroneal) vein draining into the posterior cardinal vein, which is *the FIRST embryonic vein* of the limb. This first stage of the primitive fibular/peroneal vein formation is soon followed by the second stage of the sciatic vein formation; when 'primitive fibular vein' develops two branches, 'anterior/medial tibial vein' and 'connecting branch', anterior (medial) tibial vein becomes/evolute to the main deep draining vein of the calf. Anterior tibial vein and primitive fibular veins together now

constitute the "sciatic vein", which is *the SECOND embryonic vein* (Figure 3A).

Through the third stage, 'a connecting branch' growing medially from the middle of the sciatic vein connects with a new proximal medial vessel that will become the femoral vein to establish the definitive deep venous system later, and the sciatic vein would regress. Another words, a *THIRD embryonic vein* of the leg which evolves to become the femoral vein later, grows toward the connecting branch of the lateral fibular/sciatic vein, now a part of the sciatic vein; it is further evolved with the anastomoses to sciatic veins and pass down the leg as the 'posterior tibial' vein to finish the evolution of the deep femoral vein system of the lower extremity (Figure 3B).

However, when the anterior/medial tibial vein fails to form the sciatic vein to become the main draining vein of the lower limb in the second phase of limb vessel development, subsequently a 'connecting' branch growing medially from the middle of the sciatic vein will not be able to connect with a new proximal medial vessel, the femoral vein, to become the definitive deep venous system in the third phase.

With a defect in the second stage, the lateral fibular vein will persist and become the 'marginal vein'. However, if the defect occurs in the passage

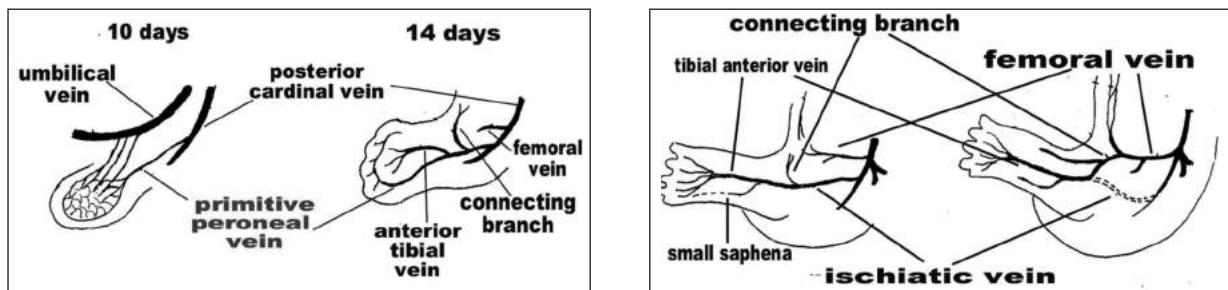


FIGURE 3: A (left photo) depicts the first stage of truncal vein development along the lower limb through the evolution of the primitive fibular (peroneal) vein as the *FIRST embryonic vein* of the lower limb. Through the second stage (right photo), 'primitive fibular vein' develops into two branches; 'anterior tibial vein' and 'connecting branch' to newly forming femoral vein. Anterior tibial vein and primitive fibular veins together now constitute the "sciatic vein", which is the *SECOND embryonic vein*.

B (left photo) illustrates the final/third stage to form the femoral vein by 'a connecting branch' from the middle of the sciatic vein, to establish new definitive deep venous system. The sciatic vein (right photo) regresses, and femoral vein is further evolved, following the anastomoses to sciatic veins, and passes down the leg as the 'posterior tibial' vein to finish the evolution of the veins along the lower limb. This third embryonic vein is also known as the precursor of long/greater saphenous vein.

(From: Lee BB. Venous embryology: the key to understanding anomalous venous conditions. *Phlebology*. 2012;19(4):170-81).

to the third stage, a 'sciatic vein' will remain as the main draining vein of the limb.

As an embryonic vein, a persisting marginal vein is always 'valveless', as the outcome of an abnormally developed vein devoid of valves and causes a severe reflux resulting in chronic venous hypertension/stasis. This abnormal vessel structure with a defective vessel wall that is deficient in smooth muscle also carries a high risk of thrombo-embolic events and infrequently lead to fatal PE,¹⁻⁵ especially among Klippel-Trenaunay Syndrome patients.¹³⁻¹⁷

The MV occurs in many different conditions with varying extent and severity (e.g. limited sciatic vein), and belongs to one group of 'lateral embryonic vein'. In addition, more than one third of patients with the MV have a defective deep venous system (e.g. hypoplasia of femoral vein, aplasia of iliac vein). Therefore, assessment of the MV is required along with precise evaluation of the deep venous system.

■ DIAGNOSIS-MARGINAL VEIN

The MV can be easily confirmed through the physical examination since the majority are quite visible as a protruding vein along the lateral aspect of the extremity. However, when it is located within thick subcutaneous fat along the swollen limb, it is not quite visible. On the other hand, they are invariably detected by a light palpation and frequently run beneath the coexisting CM known as a port wine stain.

Laboratory evaluation of the MV with Duplex ultrasonography (DUS) should include full evaluation of hemodynamic status of the MV and the deep vein system at the same time (e.g. extent and severity of the reflux and outflow resistance). Entire length/course of MV, located supra- and sub-fascially, should be visualized together with the perforators.

Non- to less- invasive tests based on the DUS, magnetic resonance imaging (MRI), and/or computerized tomography (CT) evaluation is generally sufficient for the MV assessment, but occasionally, direct puncture phlebography together with ascending phlebography would be needed as a road map for the surgical intervention (Figure 4).^{18,95}

The deep vein system should be assessed both in lying and standing positions to differentiate among normal, aplastic and hypoplastic venous segments. If there is any suspicion of pulsating flow, the arteriography may be added to rule out the AVM involved.

Another important findings along the MV among KTS patients is 'limb-length discrepancy' either as an elongation or shortening of the affected limb. A significant numbers of the MV accompany this angio-osteohypertrophy/hypotrophy known as vascular bone syndrome.⁹⁶⁻⁹⁹

They are the response/outcome of stimulation to the epiphyseal plate during the bone growth age by the nearby VM, either intraosseous or extraosseous/soft tissue lesions. These patients often have an ache or pain along the limb by the venous stasis, especially while standing.

■ TREATMENT-MARGINAL VEIN

Prophylactic anticoagulation with the weight adjusted low molecular weight heparin (LMWH) is generally recommended in all patients with the MV.¹⁰⁰⁻¹⁰³ This is especially important when the MV presents with an aplastic or hypoplastic iliac-femoral venous system. Anticoagulation is critical in this setting as the MV remains the major outflow vein of the lower extremity where the normal deep venous system is absent. In this subgroup of MV patients, thrombus within the vein would cause serious and often fatal PE.¹⁰⁴⁻¹⁰⁷

MV is invariably an indication for surgical excision since it causes various extents of acute as well as chronic complications including potentially fatal PE as explained in previous section. In patients with normal or even mildly hypoplastic deep veins, surgical excision- rarely endoluminal thermal ablation-of the MV should be considered to eliminate altered/abnormal hemodynamics as a possible source of thrombosis without compromising lower extremity blood return. Compression stockings are seldom beneficial and should not be used as a permanent regimen regardless of its symptoms.

Symptomatic MV to causing a limb-length discrepancy in childhood should be treated as soon as

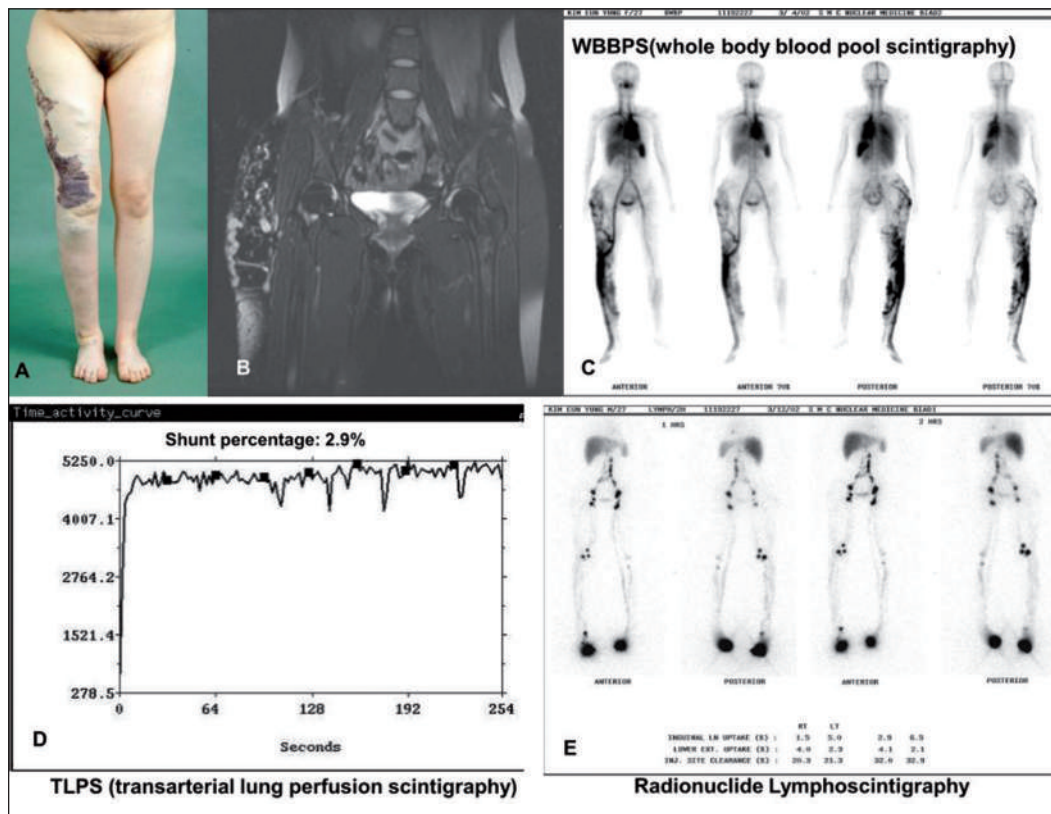


FIGURE 4: A presents clinical appearance of VM (venous malformation) lesion affecting the right lower extremity as a hemolympathic malformation (HLM), mixed with LM (lymphatic malformation) and CM (capillary malformation), often known as Klippel-Trenaunay Syndrome.

B depicts magnetic resonance imaging finding of extratruncular VM lesion diffusely infiltrating in the soft tissue and muscles of right lower extremity.

C shows WBBPS (whole body blood pool scintigraphy) findings of massive abnormal blood pool throughout entire right lower extremity; this WBBPS effectively ruled out any additional lesions throughout the body.

D illustrates TLPS (transarterial lung perfusion scintigraphy) study that is negative for abnormal AV shunting - 2.9% is within normal range.

E delineates radionuclide lymphoscintigraphy findings of anatomically normal, but functionally abnormal double (deep and superficial) lymphatic transporting vessel, visualized along right lower extremity. This finding is consistent with a clinical finding of chronic lymphedema secondary to hypoplasia of the superficial lymphatic system which is well compensated by deep system.

(From: Lee BB, Laredo J, Lee TS, Huh S, Neville R. Terminology and classification of congenital vascular malformations. *Phlebology*. 2007; 22(6):249-52).

possible to achieve length discrepancy correction. In cases with normal deep veins, complete surgical resection of the MV remains the best and most ideal treatment for the vascular bone syndrome to control the angio-osteodystrophy.^{96-99,108,109}

Due to its extremely superficial location beneath the skin, the endovascular obliteration using the laser or radiofrequency is seldom technically applicable. The foam therapy is also very difficult due to extremely large amount and relatively fast venous flow through the MV. Perforators in particular may be difficult to close and risky with this foam therapy because of potential extension of thrombosis to the deep vein system with no barriers.

However the surgical excision is also extremely difficult with high risk of bleeding. The MV often accompanies very large perforators to the deep vein so that closed stripping is almost impossible due to high risk of excessive bleeding and hematomas. Routine use of the tourniquet is strongly recommended during the surgical procedure whenever applicable. Occasionally, subfascial endoscopic perforator surgery (SEPS) is indicated for large incompetent perforating veins. MV patients who are candidates for surgical removal, should receive perioperative anticoagulation with LMWH.¹¹⁰

Nevertheless, the ablation of the MV is totally depends on the status of deep vein system; it

can be done safely only when the deep system is in normal condition to tolerate sudden increase of the venous influx following the obliteration of the MV. Otherwise, it would accompany a high risk of acute venous stasis and subsequent venous hypertension to precipitate acute venous gangrene.

However, when the deep vein system is in minimally hypoplastic condition rather than as an aplasia, the MV can be resected through multistage approach for 'rerouting of venous flow' since hypoplastic vein can dilate spontaneously to almost normal size following the resection of the MV.^{109,110} In cases of aplasia of the deep veins, the embryonal vein becomes a part of the main draining vessel of the limb and resection is not possible.

When the indolent venous ulcers is caused by the CVI of 'limited venous anomaly' origin, deep venous reconstructions can be considered for the selected case.

CONCLUSION

Marginal vein (MV) is NOT an ordinary varicose vein; it is an embryonic vein remnant with a defective vessel structure accompanying high risk of VTE. Early ablation is indicated whenever feasible especially when the MV causes a vascular bone syndrome as far as the deep vein system is normal. Otherwise, prophylactic anticoagulation is strongly recommended.

Conflict of Interest

The author declared no conflict of interest or financial support.

REFERENCES

- Vollmar J, Voss E. Vena marginalis lateralis persistens-the forgotten vein of the angiologists. *Vasa* (1979) 8:192-202.
- Lee BB. Venous embryology: the key to understanding anomalous venous conditions. *Phlebology* 2012;19(4):170-81.
- Kim YW, Lee BB, Cho JH, Do YS, Kim DI, Kim ES. Haemodynamic and Clinical Assessment of Lateral Marginal Vein Excision in Patients with a Predominantly Venous Malformation of the Lower Extremity. *Eur J Vasc Endovasc Surg* 2007;33 (1): 122-7.
- Mattassi R. Approach to marginal vein: current issue. *Phlebology* 2007;22(6):283-6.
- Weber J, Daffinger N. Congenital vascular malformations: the persistence of marginal and embryonal veins. *Vasa* 2006;35(2):67-77.
- Lee BB, Bergan JJ. Advanced management of congenital vascular malformations: a multidisciplinary approach. *J Cardiovascular Surgery* 2002;10(6):523-33.
- Lee BB. Critical issues on the management of congenital vascular malformation. *Annals Vasc Surg* 2004;18(3):380-92.
- Lee BB, Mattassi R, Loose D, Yakes W, Tasnadi G, Kim HH. Consensus on Controversial Issues in Contemporary Diagnosis and Management of Congenital Vascular Malformation—Seoul Communication. *Int J Angiol* 2004;13(4): 182-92.
- Lee BB, Villavicencio L. General Considerations. *Congenital Vascular Malformations*. Chapter 68. Section 9. Arteriovenous Anomalies. In: Cronenwett JL and Johnston KW, eds. *Rutherford's Vascular Surgery*. 7th ed. Philadelphia, PA, USA: Saunders Elsevier; 2010. p.1046-64.
- Lee BB, Laredo J, Lee TS, Huh S, Neville R. Terminology and classification of congenital vascular malformations. *Phlebology* 2007; 22(6):249-52.
- Lewis FT. Development of the veins in the limbs of rabbit embryos. *Am J Anat* 1906;5:113-20.
- von Hochstetter F. Über die Entwicklung der Extremitätsvenen bei den Amnioten. *Morph Jb Leipzig* 1891;17.1-43.
- Klippel M, Trénaunay I. Du naevus variqueux et ostéohypertrophique. *Arch Gén Méd* 1900; 3:641-72.
- Servelle M. Klippel and Trénaunay's Syndrome. *Ann Surg* 1985;201(3):365-73.
- Gloviczki P, Stanson AW, Stickler GB, Johnson CM, Toomey BJ, Meland NB, et al. Klippel-Trenaunay syndrome: the risks and benefits of vascular interventions. *Surgery* 1991;110(3): 469-79.
- Servelle M. Klippel and Trénaunay's Syndrome. 768 operated cases. *Ann Surg* 1985; 201(3): 365-73.
- Villavicencio JL. Congenital vascular malformations-predominantly venous? The Syndrome of Klippel-Trenaunay. *Scope on Phlebology and Lymphology* 2000;71(1):116-25.
- Lee BB, Bergan J, Gloviczki P, Laredo J, Loose DA, Mattassi R, et al. Diagnosis and treatment of venous malformations - Consensus Document of the International Union of Phlebology (IUP)-2009. *International Angiology* 2009;28(6): 434-51.
- Lee BB. Not all venous malformations needed therapy because they are not arteriovenous malformations. *Comments on Dermatol Surg* 2010;36(3):340-6, 347.
- Lee BB. Venous Malformation is NOT a Hemangioma. Editorial. *Flebologia Y Linfologia-lecturas Vasculares* 2012;7(17):1021-3.
- Lee BB, Laredo J. Hemangioma and Venous/Vascular malformation are different as an apple and orange! Editorial. *Acta Phlebol* 2012;13(1):1-3.
- Lee BB. Lymphedema-Diagnosis and Treatment. In: Tretbar LL, Morgan CL, Lee BB, Simonian SJ, Blondeau B, eds. Chapter 4. *Lymphatic Malformation*. London: Springer-Verlag London Limited; 2008. p.31-42.
- Lee BB, Kim YW, Seo JM, Hwang JH, Do YS, Kim DI, et al. Current concepts in lymphatic malformation (LM). *Vasc Endovasc Surg* 2005; 39(1) 67-81.
- Lee BB. Lymphedema-Angiodysplasia Syndrome: a Prodigal form of Lymphatic Malformation (LM). *Phlebology* 2005;47: 324-32.
- Berwald C, Salazard B, Bardot J, Casanova D, Magalon G. Port wine stains or capillary malformations: surgical treatment *Ann Chir Plast Esthet* 2006;51(4-5):369-72.

26. Goldman MP, Fitzpatrick RE, Ruiz-Esparza J. Treatment of port-wine stains (capillary malformation) with the flashlamp-pumped pulsed dye laser. *J Pediatr* 1993;122(1):71-7.
27. Belov S. Anatomopathological classification of congenital vascular defects. *Semin Vasc Surg* 1993;6(4):219-24.
28. Belov S. Classification, terminology, and nosology of congenital vascular defects. In: Belov S, Loose DA, Weber J, eds. *Vascular Malformations*. Reinbek, Germany: Einhorn-Press; 1989. p.25-30.
29. Rutherford RB. Classification of peripheral congenital vascular malformations. In: Ernst CB, Stanley JC, eds. *Current Therapy in Vascular Surgery*. 3rd ed. St. Louis, Mo: Mosby; 1995. p.834-8.
30. Gloviczki P, Duncan A, Kalra M, Oderich G, Ricotta J, Bower T, et al. Vascular malformations: an update. *Perspect Vasc Surg Endovasc Ther* 2009; 21(2):133-48.
31. Aggarwal K, Jain VK, Gupta S, Aggarwal HK, Sen J, Goyal V. Klippel-Trenaunay syndrome with a life-threatening thromboembolic event. *J Dermatol* 2003;30(3):236-40.
32. Walder B, Kapelanski DP, Auger WR, Fedullo PF. Successful pulmonary thromboendarterectomy in a patient with Klippel-Trenaunay syndrome. *Chest* 2000;117(5):1520-2.
33. Ulrich S, Fischler M, Walder B, Pfammatter T, Speich R. Klippel-Trenaunay syndrome with small vessel pulmonary arterial hypertension. *Thorax* 2005;60(11):971-3.
34. Johnson JN, Driscoll DJ, McGregor CG. Pulmonary thromboendarterectomy in Klippel-Trenaunay syndrome. *J Thorac Cardiovasc Surg* 2010;140(3):e41-3.
35. Leu HJ. Pathoanatomy of congenital vascular malformations. In: Belov S, Loose DA, Weber J, eds. *Vascular Malformations*. Vol 16. Reinbek, Germany: Einhorn-Press Verlag; 1989. p.37-46.
36. Leu HJ. Pathomorphology of vascular malformations: analysis of 310 cases. *Int Angiol* 1990;9(3):147-54.
37. deTakats G. Vascular anomalies of the extremities. *Surg Gynecol Obstet* 1932;55:227-37.
38. Bastide G, Lefebvre D. Anatomy and organogenesis and vascular malformations. In: Belov ST, Loose DA, Weber J, eds. *Vascular Malformations*. Reinbek: Einhorn-Press Verlag GmbH; 1989. p.20-2.
39. Woollard HH. The development of the principal arterial stems in the forelimb of the pig. *Contributions to Embryology*; 1922. p.139-54.
40. Mulliken JB, Glowacki J. Hemangiomas and vascular malformations in infants and children: a classification based on endothelial characteristics. *Plast Reconstr Surg* 1982;69(3):412-22.
41. Mulliken JB. Classification of vascular birthmarks. In: Mulliken JB, Young AE, eds. *Vascular Birthmarks: Hemangiomas and Malformations*. Philadelphia: WB Saunders; 1988. p.24-37.
42. Mulliken JB, Zetter BR, Folkman J. In vivo characteristics of endothelium from hemangiomas and vascular malformations. *Surgery* 1982; 92(2):348-53.
43. Mulliken JB. Cutaneous vascular anomalies. *Seminars in Vascular Surgery* 1993;6(4):204-18.
44. Rutherford RB. Editorial introduction. *Semin Vasc Surg* 1993;6(4):197-8.
45. Malan E. History and Nosography. *Vascular Malformations (Angiodysplasias)*. Milan, Italy: Carlo Erba Foundation; 1974. p.15-9.
46. Belov ST. Classification of congenital vascular defects. *Int Angiol* 1990;9(3):141-6.
47. Gloviczki P, Driscoll DJ. Klippel-Trenaunay syndrome: current management. *Phlebology* 2007;22(6):291-8.
48. Agrawal A, Whitehouse R, Johnson RW, Augustine T. Giant splenic artery aneurysm associated with arteriovenous malformation. *J Vasc Surg* 2006;44(6):1345-9
49. Miele VJ, Rosen CL, Carpenter J, Rai A, Bailes JE. Vertebral artery-to-middle cerebral artery bypass with coil embolization of giant internal carotid artery aneurysm: technical case report. *Neurosurgery* 2005;56(5):E1159.
50. Lee BB, Do YS, Byun HS, Choo IW, Kim DI, Huh SH. Advanced management of venous malformation (VM) with ethanol sclerotherapy: mid-term results. *J Vasc Surg* 2003;37(3):533-8.
51. Lee BB. Current concept of venous malformation (VM). *Phlebology* 2003;43:197-203.
52. Lee BB, Kim DI, Huh S, Kim HH, Choo IW, Byun HS, et al. New experiences with absolute ethanol sclerotherapy in the management of a complex form of congenital venous malformation. *J Vasc Surg* 2001;33(4):764-72.
53. Lee BB. Les malformations veineuses congénitales: évolution des concepts actuels de diagnostic et de traitement. *Angéologie* 1998; 50(4):17-19.
54. Lee BB. Fast Facts-Vascular Surgery Highlights 2006-07. Management of Arteriovenous Malformation. Health Press Limited, Elizabeth House, Queen Street, Abington, Oxford OX143LN, UK 2007. p. 42-50.
55. Lee BB. Mastery of Vascular and Endovascular Surgery. In: Zelenock GB, Huber TS, Messina LM, Lumsden AB, Moneta GL, eds. Chapter 76. Arteriovenous Malformation. Philadelphia: Lippincott, Williams and Wilkins Publishers; 2006. p. 597- 607.
56. Lee BB, Laredo J, Neville R. Arterio-venous malformation: how much do we know? *Phlebology* 2009;24(5):193-200.
57. Lee BB, Laredo J, Deaton DH, Neville RF. Arteriovenous malformations: evaluation and treatment. Gloviczki, P, ed. Chapter 53. *Handbook of Venous Disorders: Guidelines of the American Venous Forum*, 3rd ed. London, UK: A Hodder Arnold; 2009. p.583-93.
58. Lee BB, Laredo J, Seo JM, Neville R. Hemangiomas and Vascular Malformations. In: Mattassi R, Loose DA, Vaghi M, eds. Chapter 29. *Treatment of Lymphatic Malformations*. Milan, Italy: Springer-Verlag Italia, 2009. p. 231-50.
59. Lee BB, Villavicencio JL. Primary Lymphedema and Lymphatic Malformation: are they the two sides of the same coin? *Eur J Vasc Endovasc Surg* (2010) 39:646-653
60. Lee BB, Andrade M, Bergan J, Boccardo F, Campisi C, Damstra R, et al. Diagnosis and treatment of Primary Lymphedema - Consensus Document of the International Union of Phlebology (IUP)-2009. *Int Angiol* 2010; 29(5):454-70.
61. Lee BB, Laredo J, Neville RF. Primary lymphedema as a truncular lymphatic malformation. In: Lee BB, Bergan J, Rockson SG, eds. *Lymphedema: A Concise Compendium of Theory and Practice*. 1st ed. London, UK: Springer-Verlag; 2011. p.419-26.
62. Noel AA, Gloviczki P, Cherry KJ Jr, Rooke TW, Stanson AW, Driscoll DJ. Surgical treatment of venous malformations in Klippel-Trenaunay syndrome. *J Vasc Surg* 2000;32(5):840-7.
63. Gloviczki P, Hollier LH, Telander RL, Kaufman B, Bianco AJ, Stickler GB. Surgical implications of Klippel-Trenaunay syndrome. *Ann Surg* 1983;197(3):353-62.
64. Lee A, Driscoll D, Gloviczki P, Clay R, Shaughnessy W, Stans A. Evaluation and management of pain in patients with Klippel-Trenaunay syndrome: a review. *Pediatrics* 2005;115(3): 744-9.
65. Kim KH, Kim HH, Lee SK, Seo JM, Chang WY, Lee BB. OK-432 intralesional therapy for lymphangioma in children. *J Korean Assoc Pediatr Surg* 2001;7(2):142-6.
66. Park JH, Kim DI, Huh S, Lee SJ, Do YS, Lee BB. Absolute ethanol sclerotherapy on cystic lymphangioma in neck and shoulder region. *J Korean Vasc Surg Soc* 1998; 14(2):300-3.
67. Lee BB, Kim DI, Whang JH, Lee KW. Contemporary management of chronic lymphedema – personal experiences. *Lymphology* 2002;35 (Suppl):450-5.
68. Lee BB, Laredo J, Kim YW, Neville R. Congenital vascular malformations: general treatment principles. *Phlebology* 2007; 22(6):258-63.
69. Lee BB, Laredo J. Regarding-"Multidisciplinary approach in the management of a giant arteriovenous malformation in the right axillary region". *J Vasc Surg* 2008; 48(3):775-6.
70. Jeon YH, Do YS, Shin SW, Liu WC, Cho JM, Lee MH, et al. Ethanol embolization of arteriovenous malformations: results and complications of 33 cases. *J Korean Radiol Soc* 2003;49(4):263-70.

71. Lee BB, Laredo J, Deaton D, Neville R. Endovascular Treatment of Some Congenital Diseases- Hemangioma and Vascular Malformation. In: Heuser RR, Henry M, eds. Chapter 82, Section XI, Textbook of Peripheral Vascular Interventions. 2nd ed. London, UK: Informa UK Ltd; 2008. p.712-22.
72. Lee BB. Congenital Vascular Malformation. In: Geroulakos G, van Urk H, Hobson II RW, eds. Vascular Surgery: Cases, Questions and Commentaries. Chapter 41. 2nd ed. Great Britain: Springer-Verlag London Limited; 2006. p.377-92.
73. Lee BB. Amputation in an Ischaemic Limb. In: Geroulakos G, van Urk H, Hobson II RW, eds. Vascular Surgery: Cases, Questions and Commentaries. Chapter 40. 2nd ed. Great Britain: Springer-Verlag London Limited; 2003. p. 367-76.
74. Lee BB, Beaujean M, Cazoubon M. Nouvelles strategies dans la prise en charge des malformations vasculaires congenitales (MVC): un aperçu de l'expérience clinique coreenne. *Angiologie* 2004;56(2):11-25.
75. Tasnadi G. Epidemiology and etiology of congenital vascular malformations. *Semin Vasc Surg* 1993;6(4):200-3.
76. Vollmar J, Vogt K. [Angiodysplasia and the skeletal system]. *Chirurg* 1976;47(4):205-13.
77. Villavicencio JL. Congenital vascular malformations: historical background. *Phlebology* 2007;22(6):247-8.
78. Mattassi R. Historical background. In: Mattassi R, Loose DA, Vaghi M, eds. Hemangiomas and vascular malformations. An atlas of diagnosis and treatment. Milan: Springer Verlag; 2009. p.9-13.
79. Eifert S, Villavicencio JL, Kao TC, Taute BM, Rich NM. Prevalence of deep venous anomalies in congenital vascular malformations of venous predominance. *J Vasc Surg* 2000;31(3): 462-71.
80. Belov ST. Congenital agenesis of the deep veins of the lower extremity: Surgical treatment. *J Cardiovasc Surg* 1972;13: 594.
81. Raju S, Hollis K, Neglen P. Obstructive lesions of the inferior vena cava: clinical features and endovenous treatment. *J Vasc Surg* 2006; 44(4):820-7.
82. Lee BB, Villavicencio L, Kim YW, Do YS, Koh KC, Lim HK, et al. Primary Budd-Chiari syndrome: outcome of endovascular management for suprahepatic venous obstruction. *J Vasc Surg* 2006;43(1):101-8.
83. Gillespie DL, Villavicencio JL, Gallagher C, Chang A, Hamelink JK, Fiala LA, et al. Presentation and management of venous aneurysms. *J Vasc Surg* 1997;26(5):845-52.
84. Villavicencio JL, Gillespie DL, Eifert S. Venous Aneurysms: Presentation and Treatment. In: Ernst CB, Stanley JC, eds. Current Therapy in Vascular Surgery, 4th ed. Philadelphia, PA: Mosby Publ; 1999.
85. Zamboni P, Cossu A., Carpanese L., Simonetti G., Massarelli G. Liboni A. The so-called venous aneurysms. *Phlebology* 1990;5:45-50.
86. Friedman SG, Krishnasastri KV, Doscher W, Deckoff SL. Primary venous aneurysms. *Surgery* 1990;108(1):92-5.
87. Zamboni P, Pisano L, Mari C, Galeotti R, Feo C, Liboni A. Membranous obstruction of the inferior vena cava and Budd-Chiari syndrome. Report of a case. *J Cardiovasc Surg (Torino)* 1996;37(6):583-7.
88. Nedelmann M, Kaps M, Mueller-Forell W. Venous obstruction and jugular valve insufficiency in idiopathic intracranial hypertension. *J Neurol* 2009;256(6):964-9.
89. Wang ZG, Jones RS. Budd-Chiari syndrome. Current Problems in Surgery. New York: Mosby; 1996. p.83-211.
90. Lee BB, Laredo J, Deaton D, Neville R. Endovascular Management of Budd-Chiari Syndrome-Suprahepatic Inferior Vena Cava Occlusive Disease. In: Heuser RR, Henry M, eds. Textbook of Peripheral Vascular Interventions. Chapter 83, Section XII. 2nd ed. London, UK: Informa UK Ltd; 2008. p.725-31.
91. Ilijevski NS, Radak S, Novakovic B, Miholjic A, Radak D. Images in vascular medicine. Jugular vein aneurysm--ultrasonographic evaluation. *Vasc Med* 2006;11(1):51.
92. Fishman G, DeRowe A, Singhal V. Congenital internal and external jugular venous aneurysms in a child. *Br J Plast Surg* 2004;57(2):165-7.
93. Kersting S, Rössel T, Hinterseher I, Gaebler R, Litz R, Bergert H, et al. Isolated aneurysm of the internal jugular vein. *Vasa* 2008;37(4):371-3.
94. Bush S, Khan R, Stringer MD. Anterior jugular venous aneurysm. *Eur J Pediatr Surg* 1999; 9(1):47-8.
95. Lee BB, Laredo J, Lee SJ, Huh SH, Joe JH, Neville R. Congenital vascular malformations: general diagnostic principles. *Phlebology* 2007;22(6):253-7.
96. Belov ST. Correction of lower limbs length discrepancy in congenital vascular-bone diseases by vascular surgery performed during childhood. *Semin Vasc Surg* 1993;6(4):245-51.
97. Dickinson P. Venous stasis and bone growth. *Exp Med Surg* 1953;11(1):49-53.
98. Mattassi R. Differential diagnosis in congenital vascular-bone syndromes. *Semin Vasc Surg* 1993;6(4):233-44.
99. Belov S. Hemodynamic pathogenesis of vascular-bone syndromes in congenital vascular defects. *Int Angiol* 1990;9(3):155-61.
100. Gouin-Thibault I, Arkam R, Nassiri S, de la Tourette A, Conard J, Horellou MH, et al. Markers of activated coagulation in patients with factor V Leiden and/or G20210A prothrombin gene mutation. *Thromb Res.* 2002 Jul 15;107(1-2):7-11.
101. Cuderman TV, Bozic M, Peternel P, Stegner M. Hemostasis activation in thrombophilic subjects with or without a history of venous thrombosis. *Clin Appl Thromb Hemost* 2008;14 (1) 55- 62.
102. Enjolras O, Ciabrin D, Mazoyer E, Laurian C, Herbreteau D. Extensive pure venous malformations in the upper or lower limb: a review of 27 cases. *J Am Acad Dermatol* 1997;36(2 Pt 1):219-25.
103. Mason KP, Neufeld EJ, Karian VE, Zurakowski D, Koka BV, Burrows PE. Coagulation abnormalities in pediatric and adult patients after sclerotherapy or embolization of vascular anomalies. *AJR Am J Roentgenol* 2001; 177(6):1359-63.
104. Poon MC, Kloiber R, Birdsell DC. Epsilon-aminocaproic acid in the reversal of consumptive coagulopathy with platelet sequestration in vascular malformation of Klippel-Trenaunay syndrome. *Am J Med* 1989;87(2):211-3.
105. Aronoff DM, Roshon M. Severe hemorrhage complicating the Klippel-Trenaunay-Weber syndrome. *South Med J* 1998;91(11):1073-5.
106. Katsaros D, Grundfest-Broniatowski S. Successful management of visceral Klippel-Trenaunay-Weber syndrome with the antifibrinolytic agent tranexamic acid (cyclocapron): a case report. *Am Surg* 1998;64(4):302-4.
107. Yamamoto H, Muneta T, Asahina S, Furuya K, Suzuki K. Lower leg fracture with Parkes-Weber syndrome complicated by disseminated intravascular coagulation. *J Orthop Trauma* 1995;9(5):449-52.
108. Loose, DA, Lorenz, A Die Chirurgie der Maginalvene (Surgery of the marginal vein). In: Loose, DA, Weber, J: Angeborene Gefaessmissbildungen (Congenital vascular malformations) Nordlanddruck, Lüneburg. 1997. p.230-44.
109. Mattassi R. Trattamento delle angiodisplasie di tipo venoso (treatment of venous vascular malformations). In: Mattassi, R., Lose, DA, Belov, St, Vaghi, M, eds. Malformazioni vascolari ed emangiomi. Milan: Springer; 2003. p.116-23.
110. Noel AA, Gloviczki P, Cherry KJ Jr, Rooke TW, Stanson AW, Driscoll DJ. Surgical treatment of venous malformations in Klippel-Trénaunay syndrome. *J Vasc Surg* 2000;32(5):840-7.